

## Epidermal Cyst with Ossification: A Patient Report

Hiroyuki Goto, Koji Adachi, Yuichi Yoshida and Osamu Yamamoto

Division of Dermatology, Department of Medicine of Sensory and Motor Organs, School of Medicine, Tottori University Faculty of Medicine, Yonago 683-8504, Japan

### ABSTRACT

Epidermal cysts are common skin tumors that are composed of a cyst wall of epidermal cells and central keratin material. They rarely show ossification. A 68-year-old man was referred to our clinic for evaluation of multiple cysts on his left forehead, left cheek and right shoulder. Histopathological examination revealed that all of the cysts were epidermal cysts, and focal ossification was observed outside the cyst on the forehead. We speculated that chronic inflammation caused ossification around the cyst. Therefore, epidermal cyst should be included in the differential diagnosis of cysts with ossification.

**Key words** epidermal cyst; ossification; trichilemmal cyst

Epidermal cysts are common skin tumors that are composed of a keratinocytic cyst wall and central keratin material.<sup>1</sup> They usually occur in an area with abundant pilosebaceous follicles. Epidermal cysts rarely show ossification unlike other cysts such as trichilemmal cysts. Here we present an unusual case of an epidermal cyst with ossification.

### PATIENT REPORT

A 68-year-old man was referred to our clinic for evaluation of multiple cysts on his left forehead, right shoulder and right back. He had a more than 10-year history of the lesions. The sizes of the tumors were 15 mm on the forehead (Fig. 1), 20 mm on the cheek and 77 mm on the shoulder. He had a past history of inflammation around the tumors. The cysts were excised under general anesthesia. Each of the cysts was composed of a mass of epithelial cells containing keratinous material. Based on results of histopathological examination, a diagnosis of epidermal cysts was made. The tumor on

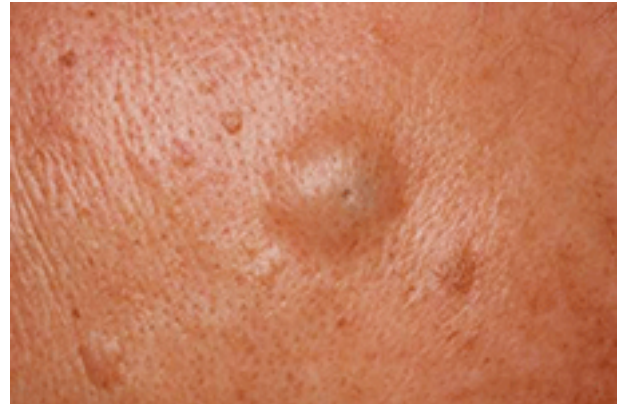

Fig. 1. Clinical feature: the tumor on the forehead.

the forehead showed focal ossification outside the cyst (Fig. 2).

### DISCUSSION

Epidermal cysts are common tumors that are composed of a cyst wall and keratin material. It is sometimes difficult to distinguish epidermal cysts from trichilemmal cysts only from clinical features. An epidermal cyst has keratohyaline granules in the cyst wall, but a trichilemmal cyst does not have such granules. In our case, keratohyaline granules were seen in the cyst wall.

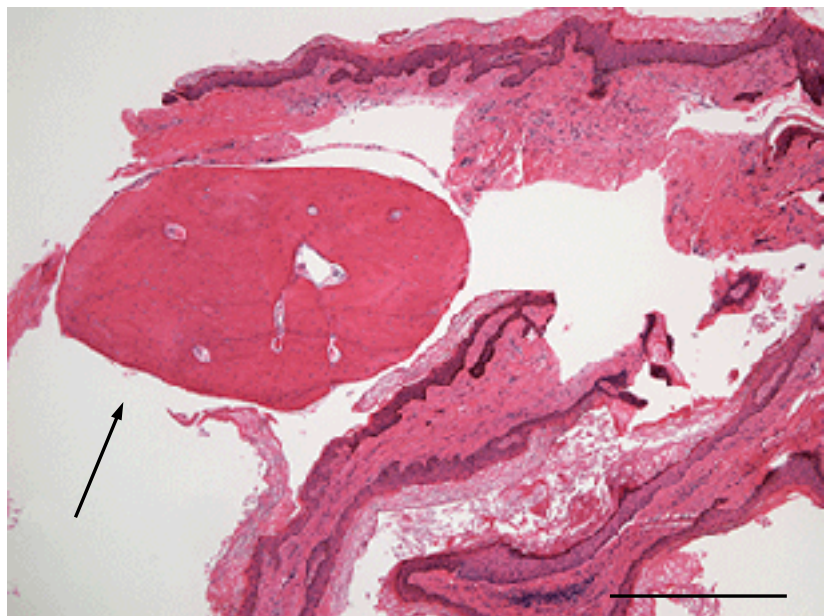


Fig. 2. Histopathological examination: the arrow shows the area of ossification area outside the cyst (hematoxylin and eosin). Bar = 500  $\mu$ m.

Corresponding author: Hiroyuki Goto, MD

h.gotou.19850820@gmail.com

Received 2013 December 24

Accepted 2014 January 8

About one quarter of trichilemmal cysts show focal calcification.<sup>1</sup> It has been reported that idiopathic calcinosis of the scrotum is associated with epidermal cyst.<sup>2</sup> However, it is rare for epidermal cysts to be accompanied by ossification. There is only one such case report in the published literature.<sup>3</sup> That case was in the testis with ossification inside the cyst. On the other hand, our patient showed ossification outside the cyst.

Satoh et al. reported that ossification might be caused by degeneration of keratin material.<sup>3</sup> We speculate that chronic inflammation caused by repeated rupture of the cyst resulted in the ossification. When we excised the cyst, we found that it had strongly adhered to surrounding tissue, suggesting the presence of chronic inflammation. In our case, when the cyst ruptured, kera-

tin material would have been scattered outside the cyst, leading to ossification around the cyst wall.

It is very rare for an epidermal cyst to show ossification, but epidermal cysts should be included in differential diagnosis of cysts with ossification.

*The authors declare no conflict of interest.*

#### REFERENCES

- 1 Weedon D. Weedon's skin pathology. 3rd edition. London: Churchill Livingstone; 2010. p. 442-3.
- 2 Saad AG, Zaatari GS. Scrotal calcinosis: is it idiopathic? Urology. 2001;57:365. PMID: 11182365.
- 3 Satoh S, Yamamoto T, Aoki H, Fuzizuka I, Kubo T, Ohhori T, et al. [Epidermoid cyst of the testis: a report of 2 cases.] Hinyokika Kyo. 1988;34:1265-8. Japanese. PMID: 3051954.