

Recent Advances in Ultrasound Imaging of Breast Lesions

Yasuaki Hirooka, Noriko Aika, Takuya Ishisugi, Masayoshi Ohguri, Chiharu Nagashima, Shota Morishita, Yosuke Kato and Chisako Fukuda

Department of Pathobiological Science and Technology, School of Health Science, Tottori University Faculty of Medicine, Yonago 683-8503, Japan

Ultrasonography works as an essential tool in diagnosing breast cancer. For mass screening of breast cancer, mammography is used worldwide as a main tool. However, in the screening of women with dense breasts and in detecting small cancer of the breast, ultrasonography is known to be more useful than mammography. Most Japanese women contract breast cancer in their 40s. Women in their 40s have more dense breasts than those in their 50s. It is expected that mass screening for breast cancer in the future will be done by a combined use of mammography and sonography. A randomized control trial of the combined use is being carried out at present in Japan. In recent years, the degree and distribution of tissue strain induced by tissue compression with an ultrasound device has enabled evaluation with color. The method, real-time tissue elastography, is used as an auxiliary tool in diagnosing diseases of various organs. Breast elastography images, classified into patterns and scores, have also begun to be widely used. Compared with conventional B-mode sonography, elastography is superior in specificity. Based on this fact, we have considered omitting available histological examinations for some breast lesions in the near future. Furthermore, elastography was useful in preoperative assessment of the margin of breast cancer. Further development of ultrasound elastography in the future is expected.

Key words: breast cancer; elastography; mass screening; ultrasonography

Role of ultrasound imaging in breast screening

In mass screening for breast cancer, women are commonly examined by inspection and palpation of the breasts (Ota et al., 1989; Kanemura et al., 1999), mammography (Kerlikowsker et al., 1995; Ohuchi et al., 1995; Jonsson et al., 2003) and sonography (Leconte et al., 2003; Yanagida et al., 2003; Osako et al., 2007; Tohno et al., 2009). In Japan, breast screening had been conducted since 1987 by interview and inspection and palpation of the breasts, but the screening produced no significant decrease in mortality (Ota et al., 1989; Kane-

mura et al., 1999). Because the usefulness of mammography had been established (Kerlikowsker et al., 1995; Ohuchi et al., 1995; Jonsson et al., 2003), breast screening with mammography was started in 2004. Actually, the number of breast cancer patients detected at mammography screening has increased. It is known, however, that mammography has a problem when used for mass screening. In Japan, breast cancer is most common among women in their 40s who tend to have dense breasts (Wakai et al., 1995). The problem with mammography screening is that its sensitivity is often decreased in dense breast tissue (Osako et al., 2007; Tohno et al., 2009). In a study on mammography screening, its sensitivity was observed to be lower in women in their 40s than in their 50s (Hasegawa et al., 2003).

Abbreviations: MR, magnetic resonance; MRI, MR imaging

On the other hand, ultrasonography has some advantages such as ease of use and no emission of radiation, so it is widely used for individual examinations for breast cancer at many medical institutions. In particular, ultrasound is superior in detecting small breast tumors 1 cm or less in diameter (Yanagida et al., 2003), and useful in mass screening of women with dense breasts (Leconte et al., 2003). In 2008, the 2nd edition of “Guideline for Breast Ultrasound: Management and Diagnosis” was published by the Japan Association of Breast and Thyroid Sonography, which contributes to better understanding of the standardized criteria for mass screening and requisites for minute examination. We examined a 74-year-old woman with mammography at breast screening. Figure 1 shows a massive image in Area C of the right breast (Fig. 1A) and a mass image in Area B of the left breast (Fig. 1B). Both were assessed as Category 3. However, the ultrasound following mammography showed the massive in the right breast to be a cyst, and the mass in the left breast

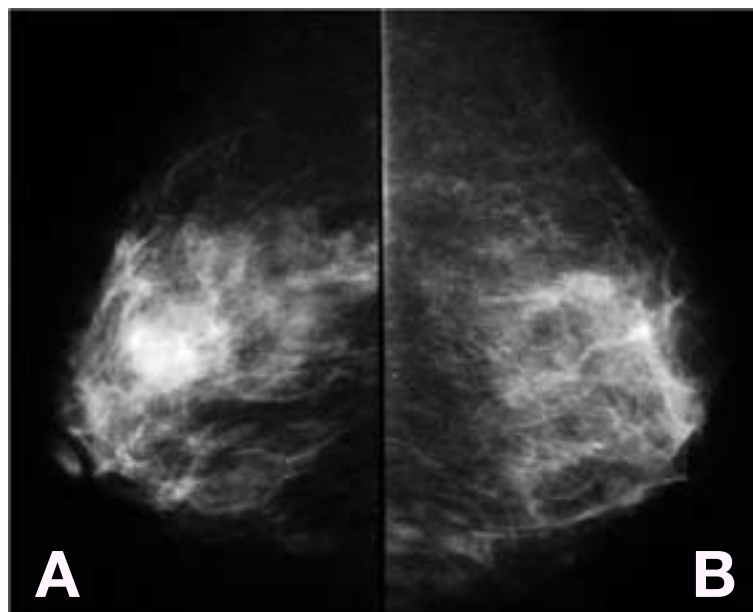


Fig.1. Mammograms obtained from a 74-year-old woman at mass screening. **A:** Massive image in the right breast, Area C. **B:** Mass image in the left breast, Area B.

to be mastopathy. Furthermore, as seen in Fig. 2, another very small mass, 5 mm in diameter, was newly discovered in the left breast area, where C bordered D. The little mass had an interruption of the mammary gland. According to the formulated criteria for breast ultrasound screening (Japan

Association of Breast and Thyroid Sonography, 2008), we assessed it as Category 4 and suspected malignancy. Examined with aspiration cytology, the patient showed positive for scirrhous carcinoma, and was treated with breast conserving surgery. As described, ultrasound seems very useful in detecting breast cancer, but its usefulness as a screening method has not clearly established. No country adopts ultrasound for breast screening at present. However, recently, performance of screening in women at high risk for breast cancer was compared between ultrasound with mammography and mammography alone (Berg et al., 2008). Adding this single technique to mammography yielded a higher detection rate of breast cancer.

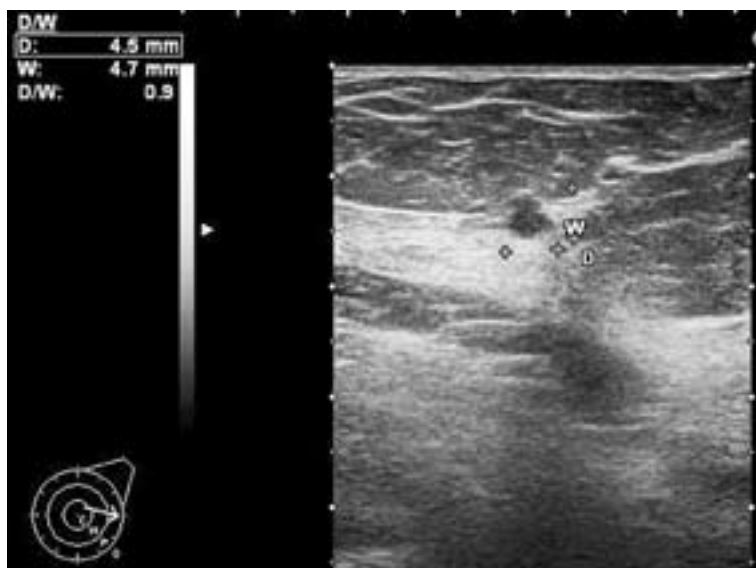

Fig. 2. Ultrasound image of the left breast of the same woman in Fig. 1 taken with conventional B-mode sonography. A mass of about 5 mm in diameter is visible in Area C, which shows an interruption into the anterior border of the mammary gland. This lesion was assessed as Category 4.

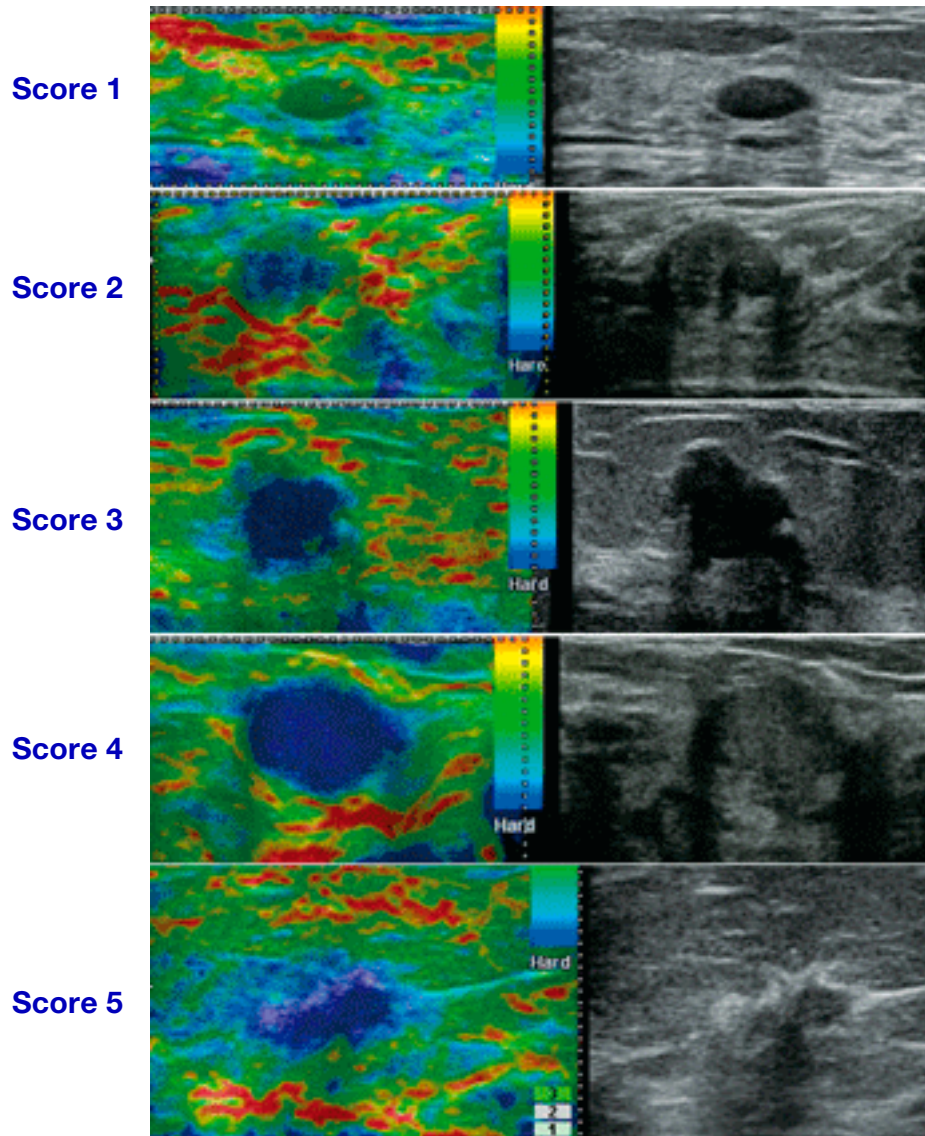


Fig. 3. Clinical images obtained from our subjective cases are classified according to the Tsukuba Elastography Score. Score 4 or over is determined to be malignant.

Because of these observations, a Japanese study group with Dr. Noriaki Ohuchi of Tohoku University as leader has started a randomized control trial to investigate the efficacy of ultrasound with mammography for breast cancer screening. We expect that results of the trial will prove the combination to be useful within a few years.

Real-time tissue elastography for breast disease

Recently, real-time tissue elastography was developed to evaluate tissue elasticity with ultrasound (Shiina et al., 2002), which has been gradually ap-

plied clinically in diagnosing breast disease (Itoh et al., 2006). This is a tissue elasticity imaging technique that visualizes the degree and distribution of strain induced by light compression in a real-time manner when artificial light compression is applied to breast tissue. Results are noted when soft tissue receives greater strain, while stiff tissue receives less (Shiina et al., 2002). Itoh and workers classified breast elastography images into 5 patterns (Fig. 3) (Itoh et al., 2006), and reported the results using the Tsukuba Elastography Score (Itoh et al., 2006; Itoh, 2007). Scores from 1 to 3 showing green images of strain with and without tense blue images are judged to be benign: (1) strain in the entire hypoechoic area; (2) strain not seen in part of the

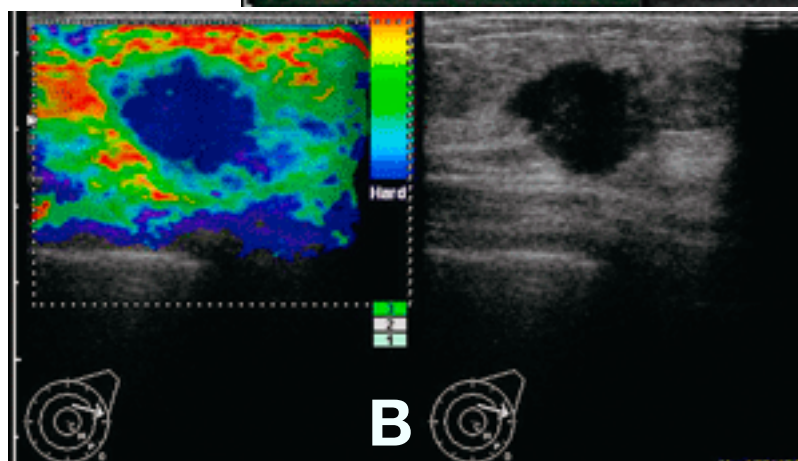
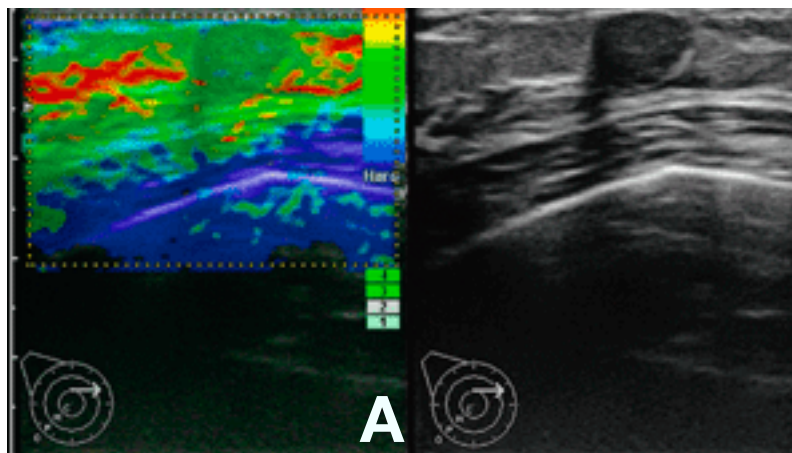


Fig. 4. Ultrasound images obtained with conventional B-mode sonography and elastography.

- A:** Fibroadenoma of the right breast assessed as Category 3 with conventional B-mode sonography (right) and Score 1 with Tsukuba Elastography Score patterns (left).
- B:** Papillotubular carcinoma of the left breast assessed as Category 4 with conventional B-mode sonography (right) and Score 4 with Tsukuba Elastography Score patterns (left).

hypoechoic area; (3) strain only in the peripheral areas and not at the center of the hypoechoic area. Scores 4 and 5 showing blue images are diagnosed as malignant: (4) no strain in the entire hypoechoic area; and (5) no strain either in the hypoechoic or surrounding areas. Figure 4 shows ultrasound images of fibroadenoma (Fig. 4A) and papillotubular carcinoma (Fig. 4B) obtained by elastography and conventional B-mode sonography. Elastography shows a green fibroadenoma mass in the region of interest (Fig. 4A left), which means that the mass is made of soft tissue. We therefore judged the score of the lesion to be 1, based on Tsukuba Elastography Score patterns. On the other hand, the whole papillotubular carcinoma in the region of interest (Fig. 4B left) is blue, that is, the mass is more solid than the surrounding tissue. We assessed this lesion as Score 4. Differentiation from benign to malignant can be made even with conventional B-mode sonography in many cases of breast disease. However, elastography has enabled examiners to

judge in a more reliable manner, visually by color. Elastography seems very useful as a subsidiary diagnostic tool for all workers from little-experienced medical technologists to skilful breast-disease specialists or medical sonographers. Table 1 shows the ratio of sensitivity, specificity and accuracy of conventional B-mode sonography and real-time tissue elastography performed in 101 patients with breast disease (61 benign and 40 malignant lesions) we have experienced. Elastography showed lower

Table 1. Comparison of ultrasound imaging techniques for breast lesions

	Sensitivity (%)	Specificity (%)	Accuracy (%)
Sonography*	90	91.8	91.1
Elastography†	77.5	100	91.1

* Conventional B-mode sonography: category 4 and over, diagnosed as malignant.

† Real-time tissue elastography: score 4 and over, diagnosed as malignant.

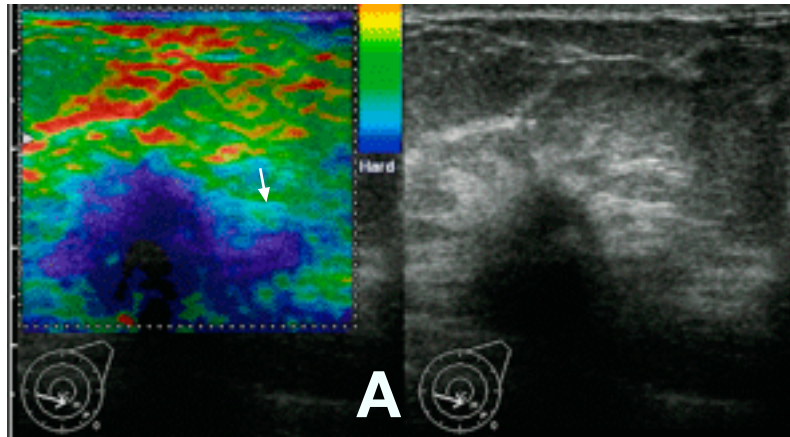
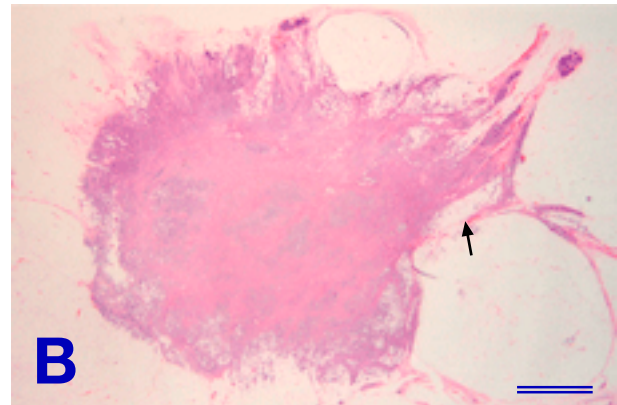


Fig. 5. Ultrasound images and pathology of a breast mass.
A: Ultrasound images of breast cancer with conventional B-mode sonography (right) and elastography (left). Elastography clearly visualizes a blue infiltration (white arrow) which is not clear with conventional B-mode sonography.
B: Histopathological appearance of the resected mass. The infiltration to the surrounding tissue (black arrow) is clear (hematoxylin and eosin stain). Bar = 3.75 mm.



sensitivity than B-mode sonography, but 100% in specificity. Furthermore, we confirmed no malignant disease for lesions determined as Score 1. It was highly expected that in the future, we can omit histological examinations such as aspiration cytology or needle biopsy for lesions judged to be Score 1 (Itoh et al., 2006; Itoh, 2007).

As described, we have great expectations in the future development of elastography. But for breasts with big lesions of wide diameter, we must learn how to give proper pressure to the breast with an ultrasound device (Sato et al., 2008) which can be achieved through complete training.

Preoperative ultrasound to achieve negative margins

Breast conserving surgery for breast cancer has become popular in these 10 and a few years. One important point of note is to avoid the risk of leaving carcinomatous lesions. For this, we must precisely grasp the degree of cancer invasion into the breast tissue and the presence and degree of the extensive

intraductal component. If the resected mass has a negative margin, the disease-free survival ratio also improves (Fortin et al., 1999). As a tool for preoperative assessment of the extent of cancer in the breast, 3-dimensional MR mammography which utilizes MRI is superior to mammography or ultrasound in providing more accurate anatomic information (Esserman et al., 1999; Nakamura et al., 2002). On the other hand, to achieve negative margins in the operating room, the usefulness of ultrasound with its easy portability and improvements in technology is well known (Henry-Tillman et al., 2001). However, ultrasound is superior in specificity but inferior to MRI in sensitivity (Tamaki et al., 2002). Considering the above facts, we applied ultrasound elastography to the assessment of the extent of breast cancer before surgery. As seen in Fig. 5, elastography clearly visualized some blue infiltration (Fig. 5A, white arrow) which was not clear with conventional B-mode sonography. Histopathological examination of the resected mass confirmed the blue depicted to be an infiltration

to the surrounding tissue (Fig. 5B, black arrow). As described above, we think that elastography is fully applicable not only to differential diagnosis between benign and malignant tumors, but also to preoperative assessment of infiltrating margins.

In conclusion, ultrasound is an essential tool in diagnosing breast cancer, and its significance at mass screening seems to increase. Elastography is a newly developed ultrasound-based function, and a very useful auxiliary tool in diagnosing breast cancer. Further development of ultrasound elastography in the future is highly expected.

References

- Berg WA, Blume JD, Cormack JB, Mendelson EB, Lehrer D, Böhm-Vélez M, et al. Combined screening with ultrasound and mammography vs mammography alone in women at elevated risk of breast cancer. *JAMA* 2008;299:2151–2163.
- Esserman L, Hylton N, Yassa L, Barclay J, Frankel S, Sickles E. Utility of magnetic resonance imaging in the management of breast cancer: evidence for improved preoperative staging. *J Clin Oncol* 1999 ;17:110–119.
- Fortin A, Larochelle M, Laverdière J, Lavertu S, Tremblay D. Local failure is responsible for the decrease in survival for patients with breast cancer treated with conservative surgery and postoperative radiotherapy. *J Clin Oncol* 1999;17:101–109.
- Hasegawa S, Ohnuki K, Nagakubo J, Kitami A, Oyama K, Koizumi R, et al. [Breast cancer imaging by mammography: effects of age and breast composition.] *Nippon Nyugan Kenshin Gakkai* 2003;12:101–107 (in Japanese).
- Henry-Tillman R, Johnson AT, Smith LF, Klimberg VS. Intraoperative ultrasound and other techniques to achieve negative margins. *Semin Surg Oncol*. 2001;20:206–213.
- Itoh A. Review of the techniques and diagnostic criteria of breast ultrasound elastography. *MEDIX* [serial online] 2007;Suppl:8–11. Available from: URL: <http://www.hitachi-medical.co.jp/medix/supple.html>
- Itoh A, Ueno E, Thono E, Kamma H, Takahashi H, Shiina T, et al. Breast disease: clinical application of US elastography for diagnosis. *Radiology* 2006;239:341–350.
- Japan Association of Breast and Thyroid Sonography. Guideline for breast ultrasound: management and diagnosis, 2nd edition. Ueno Ei, chairman. Tokyo: Nankodo; 2008. p. 58, 103–113 [in Japanese].
- Jonsson H, Nyström L, Törnberg S, Lundgren B, Lenner P. Service screening with mammography. Long-term effects on breast cancer mortality in the county of Gävleborg, Sweden. *Breast* 2003;12:183–93.
- Kanemura S, Tsuji I, Ohuchi N, Takei H, Yokoe T, Koibuchi Y, et al. A case control study on the effectiveness of breast cancer screening by clinical breast examination in Japan. *Jpn J Cancer Res* 1999;90:607–613.
- Kerlikowske K, Grady D, Rubin SM, Sandrock C, Ernster VL. Efficacy of screening mammography. A meta-analysis. *JAMA* 1995;273:149–154.
- Leconte I, Feger C, Galant C, Berliere M, Berg BV, D'Hoore W, et al. Mammography and subsequent whole-breast sonography of nonpalpable breast cancers: the importance of radiologic breast density. *AJR Am J Roentgenol* 2003;180:1675–1679.
- Nakamura S, Kenjo H, Nishio T, Kazama T, Doi O, Suzuki K. Efficacy of 3D-MR mammography for breast conserving surgery after neoadjuvant chemotherapy. *Breast Cancer* 2002;9:15–19.
- Ohuchi N, Yoshida K, Kimura M, Ouchi A, Shiiba K, Ohnuki K, et al. Comparison of false negative rates among breast cancer screening modalities with or without mammography: Miyagi trial. *Jpn J Cancer Res* 1995;86:501–506.
- Osako T, Takahashi K, Iwase T, Iijima K, Miyagi Y, Nishimura S, et al. Diagnostic ultrasonography and mammography for invasive and noninvasive breast cancer in woman aged 30 to 39 years. *Breast cancer* 2007;14:229–233.
- Ota J, Horino T, Taguchi T, Ishida T, Izuo M, Ogita M, et al. Mass screening for breast cancer: comparison of the clinical stages and prognosis of breast cancer detected by mass screening and in out-patient clinics. *Jpn J Cancer Res* 1989;80:1028–1034.
- Shiina T, Nitta N, Ueno E, Bamber JC. Real time tissue elasticity imaging using the combined autocorrelation method. *Jpn J Med Ultrasonics* 2002;29:119–128.
- Sato K, Morimoto S, Morishita S, Kato Y, Fukuda C, Hirooka Y. Evaluation of real-time tissue elastography for breast disease. *Jpn J Med Ultrasonics* 2008;35(suppl):504.
- Tamaki Y, Akashi-Tanaka S, Ishida T, Uematsu T, Sawai Y, Kusama M, et al. 3D imaging of intraductal spread of breast cancer and its clinical application for navigation surgery. *Breast Cancer* 2002;9:289–295.
- Tohno E, Ueno E, Watanabe H. Ultrasound screening of breast cancer. *Breast cancer* 2009;16:18–22.
- Yanagida Y, Koida T, Kimura M, Tamaki Y, Horikoshi H, Higuchi K, et al. Diagnosis of invasive breast cancer whose size is 1 cm or less. *Nyugan No Rinsho* 2003;18:484–485 (in Japanese).
- Wakai K, Suzuki S, Ohno Y, Kawamura T, Tamakoshi A, Aoki R. Epidemiology of breast cancer in Japan. *Int J Epidemiol* 1995;24:285–91.

Received and accepted November 12, 2009

Corresponding author: Yasuaki Hirooka, MD