

## Correlation between Ultrasound Findings of Tumor Margin and Clinicopathological Findings in Patients with Invasive Ductal Carcinoma of the Breast

Naoko Sannomiya,\* Yuiko Hattori,\* Naoyuki Ueda,\* Akira Kamida,\* Yuki Koyanagi,\* Haruki Nagira,\* Saeko Ikunishi,\* Kenta Shimabayashi,\* Yuki Hashimoto,\* Aya Murata,\* Kengo Sato,\* Yumi Hirooka,† Keiko Hosoya,† Kiyosuke Ishiguro,‡ Yoko Murata† and Yasuaki Hirooka\*

\*Department of Pathobiological Science and Technology, School of Health Science, Tottori University Faculty of Medicine, Yonago 683-8503, Japan, †Division of Breast and Endocrine Surgery, Tottori University Hospital, Yonago 683-8504, Japan and ‡Division of Breast and Endocrine Surgery, Ichinomiyanishi Hospital, Ichinomiya 494-0001, Japan

### ABSTRACT

**Background** Breast ultrasound findings regarding tumor margins are crucial in judging whether a tumor is malignant or benign. However, the relationships between the margins and clinicopathological characteristics remain largely unknown. In this study, we examined the clinicopathological characteristics of patients with invasive ductal carcinoma whose ultrasound images showed either well-defined and rough or indistinct margins.

**Methods** Of all consecutive patients diagnosed with invasive ductal carcinoma at the Division of Breast and Endocrine Surgery of Tottori University Hospital from January 2012 to December 2014, 122 patients whose ultrasound images showed either “well-defined and rough” or “indistinct” tumor margins were included in this study. Mammography and ultrasound images taken at the initial examination were reviewed. Patients were divided into two groups based on ultrasound findings of the tumor margins: the “well-defined and rough group” and the “indistinct group.” The relationships among ultrasound findings, mammography findings and clinicopathological findings were investigated in the two groups.

**Results** The well-defined and rough group was more likely to contain solid-tubular carcinoma, while the indistinct group was more likely to contain scirrhous carcinoma. The MIB-1 index was higher in the well-defined and rough group than in the indistinct group. Additionally, the proportion of patients with nuclear grade 3, estrogen receptor-negative/progesterone receptor-negative, and triple-negative breast cancer was greater in the well-defined and rough group than in the indistinct group.

**Conclusion** Invasive ductal carcinomas with well-defined and rough margins on ultrasound were likely to

be malignant and proliferative than those with indistinct margins.

**Key words** breast cancer; margin; ultrasound imaging

Breast ultrasound findings, such as the shape, margins, posterior features, and depth/width ratio of a tumor, play an important role in judging whether the tumor is malignant or benign.<sup>1, 2</sup> Hong et al.<sup>1</sup> reported that 90% of tumors with circumscribed margins on ultrasound were benign, while 86% of those with spiculated margins were malignant. Rahbar et al.<sup>2</sup> reported that 91% of tumors with circumscribed margins were benign, 67% of those with spiculated or microlobulated margins were malignant, and 50% of those with ill-defined margins were malignant.

The Guidelines for Breast Ultrasound Diagnosis by the Japan Association of Breast and Thyroid Sonology<sup>3</sup> state that the margins of tumor lesions can be grouped into circumscribed, well-defined and rough, or indistinct. These guidelines also state that tumors with circumscribed margins are more likely to be benign, while tumors with the other two types of margins are likely to be malignant.<sup>3</sup> In breast cancer, the relationship between clinicopathological characteristics and the type of tumor margins judged on ultrasound has rarely been investigated.

We examined the clinicopathological characteristics of invasive ductal carcinoma showing either well-defined and rough or indistinct margins on ultrasound.

### SUBJECTS AND METHODS

#### Patients

Of all consecutive 204 patients diagnosed with invasive ductal carcinoma at the Division of Breast and Endocrine Surgery of Tottori University Hospital from January 2012 to December 2014, six patients with a history of breast cancer, 21 invasive carcinoma of special types, 32 noninvasive carcinoma, 17 patients with treatment of neoadjuvant chemotherapy, three bilateral carcinoma were excluded. Of the other 125 patients, three patients

Corresponding author: Yasuaki Hirooka, MD, PhD

yhirooka@med.tottori-u.ac.jp

Received 2016 March 2

Accepted 2016 May 8

Abbreviations: ER, estrogen receptor; HER2, human epidermal growth factor receptor type 2; PgR, progesterone receptor; TNBC, triple negative breast cancer

whose ultrasound images showed circumscribed of the tumor margins were excluded because they are too small population to analyze the relationship between the ultrasound images of the tumor margins and their clinicopathological characteristics. Thus, 122 patients whose ultrasound images showed either “well-defined and rough” or “indistinct” tumor margins were included in this study. Mammography and ultrasound images taken at the initial examination were reviewed.

The largest masses were evaluated in patients with multicentric breast cancer.

### Clinical findings

Age, levels of tumor markers (carcinoembryonic antigen and cancer antigen 15-3) and menopause status were investigated.

### Imaging analysis

The findings of mammography and ultrasound examinations performed at the initial examination were reviewed. Patients were divided into the well-defined and rough group and the indistinct group based on the ultrasound findings of the tumor margins. Well-defined and rough margins were defined as relatively clear but rough interfaces between tumor and non-tumor regions, while indistinct margins were defined as unclear interfaces between the above two regions (Figs. 1A and B). There were 38 tumors with two types of tumor margins. Such cases were classified as a margin of more widely recognition.

Ultrasound examinations were performed with either a HI VISION Preirus diagnostic ultrasound system (Hitachi Aloka Medical, Tokyo, Japan) with a EUP-L74M linear probe (5.0–13.0 MHz) or a Noblus system (Hitachi Aloka Medical) with a EUP-L75 linear probe (5.0–18.0 MHz).

Ultrasound findings were analyzed based on the Guidelines for Breast Ultrasound Diagnosis (3rd edition),<sup>3</sup> and the following parameters were assessed: tumor size, homogeneity (homogeneous or heterogeneous),

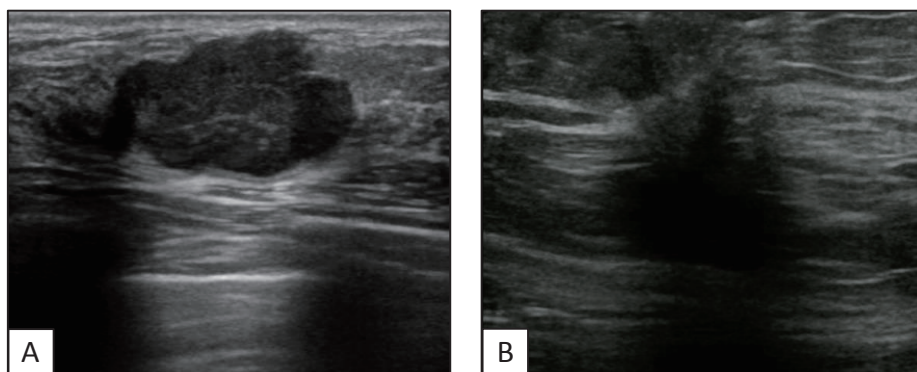
posterior features (accentuation, unchanging, or shadowing), echogenic foci (present or absent), interruption of the interface between adipose tissue and mammary gland (present or absent), and depth/width ratio ( $< 0.7$  or  $\geq 0.7$ ).

Mammographic findings were analyzed based on the Mammography Guideline (3rd expanded edition),<sup>4</sup> and the following parameters were assessed: microcalcification (present or absent), architectural distortion (present or absent), and breast density ( $< 50\%$  or  $\geq 50\%$ ).

Ultrasound images were reviewed individually by a medical breast cancer specialist with  $> 25$  years of experience and an ultrasonographer with  $> 2$  years of experience. Mammography images were reviewed by two medical breast cancer specialists with  $> 25$  years of experience in breast examination. All examiners were blinded to the patients' information during the evaluation. If there was disagreement in the evaluation of findings, a final decision was reached by consensus.

### Histological analysis

In all cases, we examined the histological classification, expression of hormone receptors [estrogen receptor (ER) and progesterone receptor (PgR)], expression of human epidermal growth factor receptor type 2 (HER2), lymphatic vessel invasion, blood vessel invasion, nuclear grade, lymph node metastasis, and MIB-1 index. The histological classifications were classified into papillotubular carcinoma, solid-tubular carcinoma, and scirrhous carcinoma in accordance with the General Rules for Clinical and Pathological Recording of Breast Cancer (17th edition),<sup>5</sup> and nuclear types were also classified in accordance with the St. Gallen International Expert Consensus on the Primary Therapy of Early Breast Cancer 2013.<sup>6</sup> Luminal A, luminal B, and HER2-positive breast cancer was termed non-triple-negative breast cancer (non-TNBC) and compared with triple-negative breast cancer (TNBC).



**Fig. 1.** Ultrasound findings of tumor margin.

**A:** An ultrasound image showed a well-defined and rough margin with posterior accentuation.

**B:** An ultrasound image showed an indistinct margin with posterior shadowing.

### Statistical analysis

The relationships among ultrasound findings, mammography findings and clinicopathological findings were investigated with respect to tumor margins in the two groups. Statistical analyses were performed with the use of statistical software, SPSS, version 23.0 (IBM, Armonk, NY), and  $P < 0.05$  indicated a statistically significant difference. Quantitative data were analyzed using Fisher's exact test and Pearson's chi-square test, while continuous data were analyzed using the Mann-Whitney  $U$  test.

This study was approved by the Ethics Committee of the Tottori University Medical School (approval number 2103).

### RESULTS

All patients were women with a mean age of 61 years (range, 28–88 years). There were no significant differences in age, tumor marker levels or menopause status between the two groups (Table 1).

The 122 patients were grouped into the well-defined and rough group ( $n = 49$ ) and the indistinct group ( $n = 73$ ). Accentuation of posterior features was observed more frequently in the well-defined and rough group, while shadowing was observed more frequently in the indistinct group ( $P < 0.001$ ) (Table 2). There were no relationships between ultrasound findings regarding margins and mammography findings (Table 3).

The pathological examination results are shown in Table 4. Tumors in the well-defined and rough group were more likely to be solid-tubular carcinomas, ER-negative, PgR-negative, nuclear grade 3, and TNBC ( $P = 0.003$ ) and to have a higher MIB-1 index. Conversely, tumors in the indistinct group were more likely to be scirrhous carcinomas ( $P < 0.001$ ), ER-positive ( $P < 0.05$ ), PgR-positive ( $P < 0.01$ ), and nuclear grade 1 ( $P = 0.001$ ) and to have a lower MIB-1 index ( $P = 0.001$ ).

**Table 1. Relationships between tumor margin type and clinical findings**

	Margin		<i>P</i> -value
	Well defined and rough	Indistinct	
Age, years old	60 (48–70)	62 (53–70)	0.441
CEA, ng/mL	1.9 (1.1–3.0)	1.6 (1.2–2.7)	0.450
CA15-3, U/mL	11.9 (8.3–16.0)	11.1 (9.3–17.8)	0.766
Menopausal status			0.186
Premenopausal	14	13	
Postmenopausal	35	60	

All variables are reported as median (interquartile range). CA15-3, cancer antigen 15-3; CEA, carcinoembryonic antigen.

### DISCUSSION

This study showed that breast cancers with well-defined and rough margins on ultrasound had a high nuclear grade and MIB-1 index, suggesting that they have a higher degree of malignancy and greater proliferative capacity. Additionally, well-defined and rough margins on ultrasound were more likely to be solid-tubular carci-

**Table 2. Relationships between tumor margin type and ultrasound findings**

	Margin		<i>P</i> -value
	Well defined and rough	Indistinct	
Tumor size, mm	17.1 (13.8–23.5)	15.2 (11.0–22.8)	0.911
Homogeneity			0.072
Homogeneous	6	19	
Heterogeneous	43	54	
Posterior features			< 0.001
Accentuation	28	13	
Unchanging	15	32	
Shadowing	6	28	
Echogenic foci			0.707
Present	21	28	
Absent	28	45	
Interrupting of the interface between adipose tissue and gland			0.635
Present	39	61	
Absent	10	12	
Depth/width ratio			0.357
< 0.7	23	28	
≥ 0.7	26	45	

Variables of tumor size are reported as median (interquartile range).

**Table 3. Relationships between tumor margin type and mammography findings**

	Margin		<i>P</i> -value
	Well defined and rough	Indistinct	
Microcalcifications			0.849
Present	17	27	
Absent	32	46	
Architectural distortion			0.099
Present	3	13	
Absent	46	60	
Breast density			0.178
< 50%	28	51	
≥ 50%	21	22	

nomas than indistinct margins. Additionally, almost all cases of TNBC were observed among the tumors with well-defined and rough margins.

Highly proliferative breast cancers reportedly do not induce a stromal reaction and thus show pushing borders, while poorly proliferative tumors induce a desmoplastic reaction resulting in the formation of dense fibrous tissue.<sup>7-9</sup> Additionally, Boisserie-Lacroix et al.<sup>10</sup>

**Table 4. Relationships between tumor margin type and pathological findings**

	Margin		P-value
	Well defined and rough	Indistinct	
MIB-1 index, %	31.0 (22.0–44.0)	20.1 (13.0–32.0)	0.001
Histological classification			< 0.001
Papillotubular carcinoma	16	24	
Solid-tubular carcinoma	21	8	
Scirrhous carcinoma	12	41	
ER			0.046
Positive	39	68	
Negative	10	5	
PgR			0.008
Positive	32	63	
Negative	17	10	
HER-2			0.635
Positive	10	12	
Negative	39	61	
Nuclear grade			0.001
Grade 1	11	34	
Grade 2	12	24	
Grade 3	26	15	
TNBC			0.003
TNBC	8	1	
non-TNBC	41	72	
Lymphatic vessel invasion			0.848
Present	19	26	
Absent	30	47	
Blood vessel invasion			1.000
Present	2	2	
Absent	47	71	
Lymph node metastasis			0.217
Present	17	17	
Absent	32	56	

Variables of MIB-1 index are reported as median (interquartile range). ER, estrogen receptor; HER2, human epidermal growth factor receptor type 2; PgR, progesterone receptor; TNBC, triple-negative breast cancer.

reported that breast cancers of low malignancy (histological grades 1 and 2) showed spiculated margins and echogenic halos around lesions attributed to a stromal reaction, while highly malignant breast cancers (histological grade 3) did not cause a stromal reaction and appeared as a round mass. It is likely that invasive ductal carcinomas with well-defined and rough margins, as seen in this study, were highly proliferative without causing a stromal reaction, and therefore grew by pushing the surrounding tissues. This theory is in agreement with another set of findings indicating that such invasive ductal carcinomas were often solid-tubular carcinomas with relatively clear margins and that accentuation of the posterior features was caused by enrichment of the cellular component. Conversely, invasive ductal carcinomas with indistinct margins were thought to be of low malignancy and caused Indian filing invasion and stromal reaction, resulting in indistinctive margins on the sonogram. Furthermore, fine stands of cancer cells infiltrating into the surrounding tissue appeared to cause backscattering, resulting in posterior shadowing.

Several studies have examined the relationships between ultrasound images and pathological findings. Çelebi et al.<sup>11</sup> showed that hormone receptor-positive breast cancers showed noncircumscribed margins with posterior shadowing, while TNBCs showed circumscribed margins. Additionally, Aho et al.<sup>12</sup> demonstrated that breast cancers showing shadowing or unchanging posterior features were histologically low-grade and ER-positive, while those showing enhanced posterior features were ER-negative. Furthermore, breast cancers with circumscribed margins, especially those in elderly patients, were highly malignant and hormone receptor-negative. These previous findings are in good agreement with our findings that invasive ductal carcinoma without indistinct margins were of nuclear grade 3 and hormone receptor-negative.

Lamb PM et al.<sup>13</sup> reported that breast cancers with shadowing posterior features on ultrasound were of histological grade 1, but they reported no significant differences in ultrasound findings regarding margins. Çeleci et al.<sup>11</sup> speculated that this was because the Breast Imaging Reporting and Data System Lexicon for Ultrasound was not used to classify the ultrasound findings. Furthermore, in contrast to our findings, Rotstein and Neerhut<sup>14</sup> showed that grade 3 invasive ductal carcinoma showed spiculated, microlobulated, and angular margins. However, Rotstein and Neerhut examined histological grade 3 cases only, and did not compare them with grade 1 and 2 cases; this may explain the difference from our findings.

TNBC is reportedly highly malignant, and the



histological grade, nuclear grade, and Ki-67 level are higher and the prognosis is poorer than those of other subtypes.<sup>15-18</sup> In terms of the relationship between ultrasound findings and breast cancer subtypes, TNBC is often associated with circumscribed margins, no shadowing of posterior features, marked hypoechogenicity, no calcification, and a large depth/width ratio.<sup>19, 20</sup> However, about 18% of TNBC tumors had circumscribed margin,<sup>21</sup> and TNBCs itself were about only 15% of all breast cancer.<sup>22</sup> Thus, TNBC tumors with circumscribed margins are small part in all breast cancer, and it was thought that many of tumors with circumscribed margin would be benign lesions. Actually, tumors with circumscribed margin were only three cases in this study. Furthermore, our study also showed that there were more TNBCs among invasive ductal carcinomas with well-defined and rough margins than among those with indistinct margins.

In this study, the patients with large tumors were excluded because they received neoadjuvant chemotherapy. This result may explain that there was no relationship between tumor margin types and tumor size.

Poor prognostic factors of invasive ductal carcinoma include young age, vessel invasion, high tumor diameter, high nuclear grade, high histological grade, high degree of proliferation, absence of hormone receptor expression, overexpression of HER2, and lymph node metastasis.<sup>6, 23, 24</sup> In addition, the expression levels of the hormone receptors Ki-67 and HER2 are particularly important in determining the optimal therapeutic strategy.<sup>6</sup> The present study showed that invasive ductal carcinomas with well-defined and rough margins on ultrasound comprised a large proportion of hormone receptor-negative cancers, high nuclear grades, TNBCs and high MIB-1 indices, suggesting a poor prognosis in these cases. This knowledge can predict important prognostic and therapeutic factors such as the proliferative potential and expression levels of hormones by ultrasound, making it possible to predict the prognosis and determine the optimal therapeutic strategy earlier.

Our study has several limitations. First, our results are not applicable to noninvasive carcinoma or invasive carcinoma of special types because these carcinomas were excluded in this study. Second, the amount of stromal tissue changes and invasion types were not assessed by histopathology. This needs to be done to investigate the relationship between histopathologic findings and ultrasound findings.

In conclusion, invasive ductal carcinomas with well-defined and rough margins on ultrasound are more likely to be malignant and proliferative than those with indistinct margins.

*The authors declare no conflict of interest.*

## REFERENCES

- Hong AS, Rosen EL, Soo MS, Baker JA. BI-RADS for sonography: positive and negative predictive values of sonographic features. *AJR Am J Roentgenol.* 2005;184:1260-5. PMID: 15788607.
- Rahbar G, Sie AC, Hansen GC, Prince JS, Melany ML, Reynolds HE, et al. Benign versus malignant solid breast masses: US differentiation. *Radiology.* 1999;213:889-94. PMID: 10580971.
- The Japan Association of Breast and Thyroid Sonology. Guideline for Breast Ultrasound – Management and Diagnosis, 3rd Ed. Tokyo: Nankodo; 2014. p. 64-7, 72-81. Japanese.
- Japan Radiological Society/ Japanese Society of Radiological Technology. Mammography Guideline 3rd Augmented Ed. Tokyo: Igaku-shoin; 2014. p. 45-51, 61. Japanese.
- The Japanese Breast Cancer Society. General Rules for Clinical and Pathological Recording of Breast Cancer. 17th Ed. Tokyo: Kanehara-shuppan; 2012. p. 25-6, 65. Japanese.
- Goldhirsch A, Winer EP, Coates AS, Gelber RD, Piccart-Gebhart M, Thürlimann B, et al. Personalizing the treatment of women with early breast cancer: highlights of the St Gallen International Expert Consensus on the Primary Therapy of Early Breast Cancer 2013. *Ann Oncol.* 2013;24:2206-23. PMID: 23917950.
- Blaichman J, Marcus JC, Alsaadi T, El-Khoury M, Meterissian S, Mesurole B. Sonographic appearance of invasive ductal carcinoma of the breast according to histologic grade. *AJR Am J Roentgenol.* 2012;199:W402-8. PMID: 22915433.
- Tilanus-Linthorst M, Verhoog L, Obdeijn IM, Bartels K, Menke-Pluymers M, Eggermont A, et al. A BRCA1/2 mutation, high breast density and prominent pushing margins of a tumor independently contribute to a frequent false-negative mammography. *Int J Cancer.* 2002;102:91-5. PMID: 12353239.
- Costantini M, Belli P, Bufi E, Asunis AM, Ferra E, Bitti GT. Association between sonographic appearances of breast cancers and their histopathologic features and biomarkers. *J Clin Ultrasound.* 2016;44:26-33. PMID: 26402438.
- Boisserie-Lacroix M, Mac Grogan G, Debled M, Ferron S, Asad-Syed M, Brouste V, et al. Radiological features of triple-negative breast cancers (73 cases). *Diagn Interv Imaging.* 2012;93:183-90. PMID: 22421282.
- Çelebi F, Pilancı KN, Ordu Ç, Ağacayak F, Alço G, İlgin S, et al. The role of ultrasonographic findings to predict molecular subtype, histologic grade, and hormone receptor status of breast cancer. *Diagn Interv Radiol.* 2015;21:448-53. PMID: 26359880.
- Aho M, Irshad A, Ackerman SJ, Lewis M, Leddy R, Pope TL, et al. Correlation of sonographic features of invasive ductal mammary carcinoma with age, tumor grade, and hormone-receptor status. *J Clin Ultrasound.* 2013;41:10-7. PMID: 22996916.
- Lamb PM, Perry NM, Vinnicombe SJ, Wells CA. Correlation between ultrasound characteristics, mammographic findings and histological grade in patients with invasive ductal carcinoma of the breast. *Clin Radiol.* 2000;55:40-4. PMID: 10650109.
- Rotstein AH, Neerhut PK. Ultrasound characteristics of histologically proven grade 3 invasive ductal breast carcinoma. *Australas Radiol.* 2005;49:476-9. PMID: 16351611.
- Carey LA, Dees EC, Sawyer L, Gatti L, Moore DT,

- Collichio F, et al. The triple negative paradox: primary tumor chemosensitivity of breast cancer subtypes. *Clin Cancer Res.* 2007;13:2329-34. PMID: 17438091.
- 16 Liedtke C, Mazouni C, Hess KR, André F, Tordai A, Mejia JA, et al. Response to neoadjuvant therapy and long-term survival in patients with triple-negative breast cancer. *J Clin Oncol.* 2008;26:1275-81. PMID: 18250347.
- 17 Stathopoulos GP, Malamos NA, Markopoulos C, Polychronis A, Armakolas A, Rigatos S, et al. The role of Ki-67 in the proliferation and prognosis of breast cancer molecular classification subtypes. *Anticancer Drugs.* 2014;25:950-7. PMID: 24949917.
- 18 Sato I, Yamaguchi M, Ishida T. Triple Negative and Younger Cases in Breast Cancer Showed Higher Ki-67 Proliferation Index, Nuclear Grade and Histological Grade. *Journal of Japanese College of Surgeons.* 2013;38:721-5.
- 19 Ko ES, Lee BH, Kim HA, Noh WC, Kim MS, Lee SA. Triple-negative breast cancer: correlation between imaging and pathological findings. *Eur Radiol.* 2010;20:1111-7. PMID: 19898850.
- 20 Jung HK, Han K, Lee YJ, Moon HJ, Kim EK, Kim MJ. Mammographic and sonographic features of triple-negative invasive carcinoma of no special type. *Ultrasound Med Biol.* 2015;41:375-83. PMID: 25542493.
- 21 Li B, Zhao X, Dai SC, Cheng W. Associations between mammography and ultrasound imaging features and molecular characteristics of triple-negative breast cancer. *Asian Pac J Cancer Prev.* 2014;15:3555-9. PMID: 24870756.
- 22 Reis-Filho JS, Tutt AN. Triple negative tumours: a critical review. *Histopathology.* 2008;52:108-18. PMID: 18171422.
- 23 Yerushalmi R, Woods R, Ravdin PM, Hayes MM, Gelmon KA. Ki67 in breast cancer: prognostic and predictive potential. *Lancet Oncol.* 2010;11:174-83. PMID: 20152769.
- 24 Fitzgibbons PL, Page DL, Weaver D, Thor AD, Allred DC, Clark GM, et al. Prognostic factors in breast cancer. College of American Pathologists Consensus Statement 1999. *Arch Pathol Lab Med.* 2000;124:966-78. PMID: 10888772.