

## Transurethral *En Bloc* Resection of Bladder Tumor Using an Endoscopic Submucosal Dissection Technique: Preliminary Results in an Animal Model

Shuichi Morizane,\* Takehiro Sejima,\* Hideto Iwamoto,\* Toshihiko Masago,\* Masashi Honda,\* Yuichiro Ikebuchi,† Kazuya Matsumoto,† Masaru Ueki‡ and Atsushi Takenaka\*

\*Division of Urology, Department of Surgery, School of Medicine, Tottori University Faculty of Medicine, Yonago 683-8503, Japan,

†Department of Gastroenterology, School of Medicine, Tottori University Faculty of Medicine, Yonago 683-8503, Japan and ‡Center for Promoting Next-Generation Highly Advanced Medicine, Tottori University Hospital, Yonago 683-8504, Japan

### ABSTRACT

**Background** Transurethral resection of bladder tumor (TURBT) technique has been considered the routine method for removing most bladder tumors for decades. In contrast, endoscopic submucosal dissection (ESD) is the gold-standard treatment for gastrointestinal superficial tumors. We investigated the effectiveness and applicability of a new technique for *en bloc* bladder tumor resection using ESD procedure.

**Methods** Four Landrace Large White Duroc female pigs were anesthetized with isoflurane prior endoscopic resection using a large-caliber prototype fiber bronchoscope. After local infiltration of the submucosa with sodium hyaluronate using an injector needle, a section of the target area (1.0–2.0 cm diameter circular area) was cut with the Dual Knife.

**Results** In total, seven target sections were resected from the pigs. The median size of the resected sections was 1.8 cm (range 1.0–2.5 cm) and the median time taken to perform the resection of one section was 20 min (range 4–35 min). These target sections were completely resected *en bloc*. Although the small bladder perforations occurred on two occasions, no other short-term complications such as uncontrollable bleeding were observed.

**Conclusion** This procedure is a slightly difficult in the pigs with thin bladder walls. However, this procedure with the slim flexible cystoscope may allow us to be able to remove bladder tumors using only light sedation, especially for cases when small tumor recurrence is observed during routine cystoscopy for the patients with non-muscle invasive bladder cancer.

**Key words** endoscopic surgical procedure; carcinoma; transurethral resection; urinary bladder

Bladder cancer is the fourth most common cancer in men, and accounts for 10,410 cancer-related deaths per year.<sup>1</sup> Approximately, 70% are presented as non-muscle invasive bladder cancer (NMIBC). Most Ta and T1 bladder tumors are treated with the transurethral resection of bladder tumor (TURBT) technique, which involves

the laser resection and the wire loop resection. This technique is considered the routine method for removing most bladder tumors for several decades, and it aims to ensure accurate histological diagnosis and remove all visible lesions. However, TURBT is not ideal to obtain tumor samples for pathological evaluation because of inaccuracies in determining the exact orientation of the tumor and tissue fragmentation. The presence of bladder muscularis propria within the tumor is used to discriminate between NMIBC and muscle invasive bladder cancer.<sup>2, 3</sup> Maruniak et al. reported that bladder muscularis propria is absent in up to 51% of bladder cancers treated with conventional TURBT.<sup>4</sup> Richterstetter et al. also reported relatively high residual tumor rates, reaching 16% in patients with pTa tumors and 38% in patients with NMIBC. In addition, they concluded that an extended TURBT provides detailed information about the horizontal and vertical extent of the bladder tumor lesion.<sup>5</sup> The failure to detect bladder muscularis propria within the tumor tissue is likely to lead to understaging or a redundant second TURBT.

Over the last decades, several studies have focused on the development of new techniques based on transurethral *en bloc* resection of bladder tumors.<sup>6–11</sup> In the gastrointestinal tract, endoscopic mucosal resection and endoscopic submucosal dissection (ESD) have become the standard procedures for the treatment of superficial tumors.<sup>12, 13</sup> In the present study, we evaluated the application of this technique and the use of a Dual Knife to resect bladder tumors in an animal model.

### MATERIALS AND METHODS

#### Ethics

This study was approved by the Tottori University Animal Ethics Committee (12-Y-57), and the animals received human care throughout the experiment.

Corresponding author: Shuichi Morizane, MD, PhD

morizane@med.tottori-u.ac.jp

Received 2016 March 11

Accepted 2016 April 11

Abbreviations: ESD, endoscopic submucosal dissection; NMIBC, non-muscle invasive bladder cancer; TURBT, Transurethral resection of bladder tumor

## Animals


Four Landrace Large White Duroc female pigs (35–40 kg) were used in this study. The animals were fed regularly until 24 h before the surgical procedure; thereafter they were starved with free access to water. After the experiment was completed, the animals were killed using a lethal dose of potassium chloride, after which necropsy was performed.

## Anesthesia

The pigs were premedicated with an intramuscular dose of ketamine hydrochloride (10 mg/kg) and xylazine hydrochloride (2 mg/kg). Subsequently, they were intubated with a 6.5-mm endotracheal tube cuffed, inflated to prevent air leaks and mechanically ventilated, and anesthetized with isoflurane. The animals remained anesthetized throughout the study with doses ranging from 2.0% to 3.0%.

## Equipment

A large-caliber prototype fiber bronchoscope (FB-19TX; PENTAX, Tokyo, Japan) was used to perform the endoscopic resections (Fig. 1a). This tool is a large-caliber endoscope with a 6.2-mm diameter insertion tube and a 3.2-mm diameter instrument channel. An injector needle (Impactflow H type 25 gauge, insertion tube 2.6-mm diameter, needle length 4 mm; TOP, Tokyo, Japan), an electro-surgical knife (Dual Knife, insertion tube 2.7-mm diameter, needle length 2.0 mm; Olympus Medical Systems, Tokyo, Japan), and a tissue recovery bag (Roth Net; Olympus Medical Systems, Tokyo, Japan) were the list of endoscopic instruments used. Dual Knife is a novel single-use electro-surgical knife with a 2-mm razor blade, commonly used for gastrointestinal tract ESD (Fig. 1b). It has a knob-shaped tip and a non-adjustable-knife length, which makes the needle less likely to slip and



**Fig. 1.** Photograph of (a) the Large-caliber prototype fiber bronchoscope, and (b) the Dual Knife.

penetrate the surrounding non-target tissue during resection. An ERBOTOM ICC 200 (Erbe Elektromedizin GmbH, Tübingen, Germany) was used as an electro-surgical generator.

## Surgical procedure

The endoscopic resection procedure was performed as follows:

- i) The fiber bronchoscope was introduced through the urethra allowing for visual inspection of the bladder. Using the endoscope, all the urine was collected from the bladder and 100–150 mL of ambient air was introduced into the bladder using an injector.
- ii) A circular area of 1.0–2.0-cm diameter was defined in the bladder with the Dual Knife using an electro-surgical current (Forced coagulation mode 20 W) and identified as the target area for resection. This procedure was omitted in some cases.
- iii) After locally infiltrating the submucosa with a solution of sodium hyaluronate (MucoUp; Johnson and Johnson, Tokyo, Japan) or glycerol (Fig. 2a), we made an incision around the target area using the Dual Knife (Endo Cut mode 120 W; Fig. 2b).
- iv) Through the proximal incision, we injected MucoUp into the muscle layer around the target area to lift the lesion.
- v) A section of the target area was cut using the Dual Knife (Swift Coag mode 25 W) excising the target following a procedure similar to that of ESD (Fig. 2c).
- vi) The resected section was retrieved using a Roth Net through the urethra (Figs. 2d and e).
- vii) After the animal was euthanized, the bladder was extracted via laparotomy and dissected for macroscopic examination.

## RESULTS

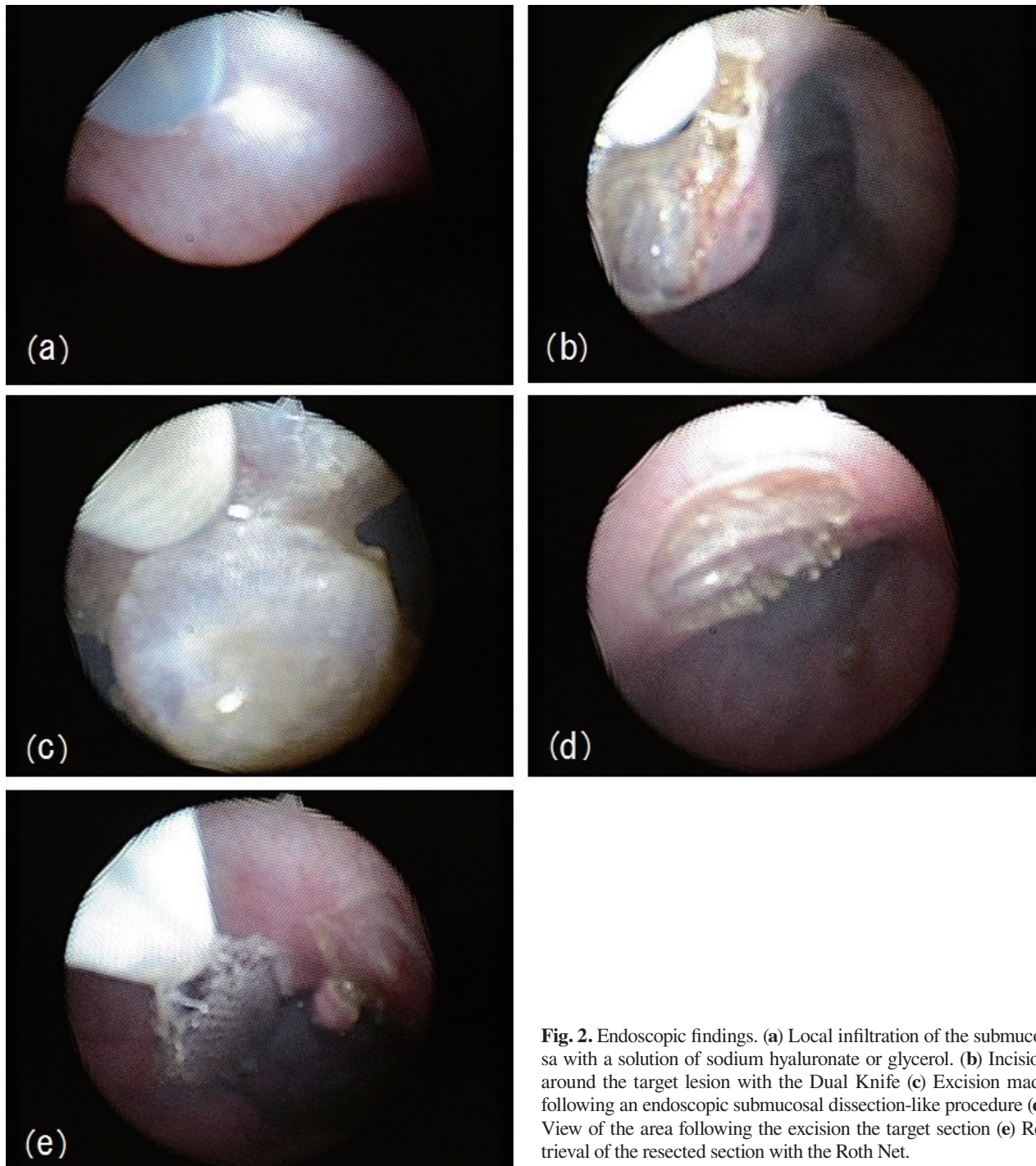
Endoscopy of the bladder using a fiber bronchoscope was technically feasible in all the animals. Seven of the eight target sections were successfully resected from the four pigs. However, because we took 60 min or more in the 2nd procedure, we gave up the one excision out of the eight target sections. In the seven procedures, the median size of the resected pieces *ex vivo* was 1.8 cm (range 1.0–2.5 cm), and the median time taken to surgically resect each target piece was 20 min (range 4–35 min). The time required to perform a resection decreased as the surgeon became familiarized with the procedure. The first four resections took approximately 26.5 min each whereas the time taken for the last three resections averaged 9 min.

All the seven target sections could be completely resected *en bloc*; however, because the pieces contained

a considerable portion of muscular tissue, the complications from the small bladder perforation developed in two of the seven operations performed. No other short-term complications, such as uncontrollable bleeding were observed. Figure 3 shows the presence of muscular tissue both in the target section and in the corresponding section of the bladder. The depth of the dissection was almost controlled by injecting MucoUp into the muscle layer around the target section.


## DISCUSSION

In this animal model experiment, we demonstrated the feasibility of a new transurethral ESD-like *en bloc* resection, using the Dual Knife based on the ESD procedure commonly used to extract superficial tumors from the gastrointestinal tract. Using this method, the target lesions can be resected in one piece and the resection can be performed endoscopically. Although we can resect the bladder tumors at all locations of the bladder by the



**Fig. 2.** Endoscopic findings. (a) Local infiltration of the submucosa with a solution of sodium hyaluronate or glycerol. (b) Incision around the target lesion with the Dual Knife (c) Excision made following an endoscopic submucosal dissection-like procedure (d) View of the area following the excision the target section (e) Retrieval of the resected section with the Roth Net.





**Fig. 3.** Histological image showing (a) a resected target section, and (b) a resected bladder (hematoxylin and eosin staining; Bar = 900  $\mu$ m).

conventional TURBT after obtaining enough skills, it is difficult to resect the tumors near the dome of the bladder where a loop electrode touches perpendicularly. The resection near the dome of the bladder was also difficult in this study, and we were not able to resect completely in the 2nd procedure.

It has been confirmed that the absence of detrusor muscle in the specimen is associated with a significantly higher risk of residual disease, early recurrence and tumor understaging.<sup>14</sup> Although deep resection can potentially result in bladder perforations, urologists have to obtain a certain detrusor muscle with the bladder tumor for the purpose of diagnosis and treatment. Therefore, as Nieder et al. have previously described, the surgeons must take into consideration the tumor appearance and the need to obtain muscle, the bladder thickness, and the depth of penetration of the loop into the wall as the current is applied.<sup>15</sup> We also consider that it is very important for the ESD procedure as well as for the TURBT. The Dual Knife used in our study enabled us to obtain a reasonable amount of tissue from the muscle layer. Its knob-shaped tip and non-adjustable length (2 mm) make the needle less likely to slip and enables easy penetration into the surrounding non-target tissue during the resection of the lesion. This procedure allowed the retrieval of the target tissue, containing a minor section of the muscle layer at its base and without bladder perforation, even in those cases when the bladder was not sufficiently dilated and injected MucoUp into the muscle layer sufficiently. In addition, we found that the time required to perform this surgery decreased as the surgeon became familiarized with the slim flexible cystoscope and the Dual Knife, suggesting that some training would be

required to become sufficiently skilled to perform this procedure within a reduced time frame.

Transurethral ESD-like *en bloc* resection is a slightly difficult procedure, particularly during muscular incision with the Dual Knife, and it carries a risk of perforation if the muscle is not injected with a solution such as MucoUp in this animal model. In the present study, MucoUp administration created a prominent long-lasting muscular elevation, which allowed the safe placement of circumferential and bottom incisions around the target region except for two cases. Although there is no evidence about the injection with solution into the muscle layer, we considered that these small perforations could be prevented by injecting MucoUp into the muscle layer repeatedly. On the other hand, the organs outside of the bladder may be protected by injecting MucoUp under the target sections, even when small bladder perforation occurred. Previously, Nieder et al. reported the complication rates about the bleeding and the bladder perforations associated with TURBT.<sup>15</sup> They concluded that the transfusion was required in 0.9 to 13% and the bladder perforation was occurred in 1.3 to 5%. However we usually experience some bleeding at TURBT, we terminate the operations after carefully stopping the bleeding by cauterization. Therefore, we have not frequently experienced the hemorrhage requiring transfusions. We consider that the bleeding is not a problem except for the large or multiple bladder tumors. Hypothetically speaking, if we experienced a small bladder perforation, we would manage it conservatively with urethral catheter drainage a little longer than the patients without bladder perforations. Therefore, we consider that the ESD procedure can be applied similar to TURBT for the patients with small bladder tumors.

Yamamoto et al. reported on the use of MucoUp as a submucosal injection in colorectal and gastric endoscopic resections.<sup>16, 17</sup> The bladder wall is thicker than the gastrointestinal wall and decreases with increasing bladder volume.<sup>18</sup> Although the mean wall thickness of the gastric antrum and rectum are 2.9 ( $\pm$  0.8) mm and 2.1 ( $\pm$  0.5) mm, respectively,<sup>19</sup> that of the bladder of a healthy adult human is approximately 3.35 mm.<sup>18</sup> Therefore, we propose that performing ESD in the bladder (of an adult human bladder of approximately 100 mL in volume) is comparatively safer than performing ESD in the gastrointestinal tract.

The *en bloc* TUR technique was first described in 1997, and it has been acknowledged to improve pathological staging;<sup>6-8, 20</sup> however, this procedure is suitable to retrieve small tumors, because they are retrieved using a resectoscope with a standard evacuator. Naselli et al. reported a technical modification that allows retrieval

of tissue sections of up to 4.5 cm using laparoscopic forceps.<sup>10</sup> On the other hand, Lodde et al. reported the limitations of using *en bloc* techniques for tumors larger than 2.5 cm in diameter.<sup>9</sup> Considering that the diameter of the urethra is approximately 1.0 cm, the size of the tumor which can be retrieved in one piece through the urethra is limited. We also acknowledge the difficulties associated with the retrieval of tumors larger than 2.5 cm in one piece using this technique, and therefore, suggest that conventional TURBT is unavoidable for larger tumors. Furthermore, although endoscopic cold cup biopsy forceps and hot cup forceps can be used to retrieve tumor specimens for pathological evaluation, these methods are limited to those specimens whose sizes are below those of the inner diameter of the cystoscopic working channel and the cup size.<sup>21, 22</sup> These methods are highly efficient for small tumors, and it is thus difficult to perform an *en bloc* resection for tumors larger than 5 mm. Although our technique also presents some limitations to perform *en bloc* resections for big tumors, this method is useful to resect tumors up to 2.5 cm and is more effective than cup biopsy.

Despite TURBT being the routine method for both primary and repeated treatment of bladder tumors, this technique is prone to tissue fragmentation, possibly causing an early recurrence of NMIBC because of the implantation of detached cancer cells into the bladder urothelium following resection.<sup>23</sup> The use of conventional TURBT led to a larger number of tumor fragments, necessitating the use of an evacuator for complete retrieval. Consequently, a high intravesical pressure may be created during the process of tumor retrieval. El-Abbady et al. showed that some malignant cells penetrate through the denuded urothelium during TURBT because of the presence of high intravesical pressure, which may result in tumor recurrence at later stages.<sup>24</sup> One-piece resection is considered the gold standard for gastrointestinal endoscopic mucosal resection, because it allows for an accurate histological assessment and reduces the risk of recurrence.<sup>25, 26</sup> In addition, ESD reportedly improves the rate of successful *en bloc* resection in the gastrointestinal tract;<sup>27, 28</sup> therefore, we would expect that these *en bloc* procedures may also decrease the risk of recurrence in the case of NMIBC.

We believe that the pain associated with the transurethral procedure can be reduced with a slim endoscope. With this procedure, we may be able to remove bladder tumors using only light sedation, especially for cases when small tumor recurrence is observed during routine cystoscopy for the patients with NMIBC. For the reasons discussed above, this method is primarily recommended for small and non-multiple bladder cancer.

We also consider that this method would help reduce the medical costs and the waiting period associated with the treatment of this type of tumors. Furthermore, we expect it to lead to improvements in histological assessments, and to reduce the risk of recurrence by maintaining tissue integrity, thereby limiting tumor seeding. Because of its potential to replace current bladder cancer treatment, further investigations are warranted.

As previously reported, a main advantage of air over water cystoscopy is its lower costs associated.<sup>29</sup> Ciudin et al. showed a lack of statistical differences between water cystoscopy and air cystoscopy in patients without hematuria, whereas the latter presented a higher diagnostic sensitivity and specificity in such patients.<sup>30</sup> In the present study, the endoscopic view during air cystoscopy was not particularly good due to the discharge of urine, the smoke from the electrotome, and the use of an older type of fiber bronchoscope. At the time of the experiment, a slim flexible cystoscope with a large instrument channel, which allowed the insertion of a large instrument such as the Dual Knife, was not available. New instruments combining a slim insertion tool and a channel diameter, allowing the insertion of larger instruments while allowing for the adjustment of air injection and evacuation, should be developed to provide easy use and high stability for transurethral ESD-like *en bloc* resection.

This pilot study was conducted in a small number of Landrace Large White Duroc pigs. In the present study, the small bladder perforations occurred in two of the seven operations performed. The thickness of the bladder wall of a pig is less than half of that of a human, creating an additional difficulty; however, because the bladder wall is thicker in humans, we consider the possibility of bladder perforation to be even lower in humans, more so if the resection is performed more carefully and using injection MucoUp into the muscle layer repeatedly. Despite this limitation, we have confirmed that transurethral ESD-like *en bloc* resection could be performed relatively safely and correctly. The present findings can be regarded as a significant step in the field. We are hoping to apply this technique to treat bladder tumors in human.

In conclusion, transurethral ESD-like *en bloc* resection using the Dual Knife is a slightly difficult procedure in the pigs with thin bladder walls in this study. However, this procedure with the slim flexible cystoscope may allow us to be able to remove bladder tumors using only light sedation, especially for cases when small tumor recurrence is observed during routine cystoscopy for the patients with NMIBC.

*The authors declare no conflict of interest.*

## REFERENCES

- 1 Jemal A, Siegel R, Xu J, Ward E. Cancer statistics, 2010. *CA Cancer J Clin.* 2010;60:277-300. PMID: 20610543.
- 2 Dutta SC, Smith JA, Jr., Shappell SB, Coffey CS, Chang SS, Cookson MS. Clinical under staging of high risk nonmuscle invasive urothelial carcinoma treated with radical cystectomy. *J Urol.* 2001;166:490-3. PMID: 11458053.
- 3 Weizer AZ, Wasco MJ, Wang R, Daignault S, Lee CT, Shah RB. Multiple adverse histological features increase the odds of under staging T1 bladder cancer. *J Urol.* 2009; 182:59-65. PMID: 19447443.
- 4 Maruniak NA, Takezawa K, Murphy WM. Accurate pathological staging of urothelial neoplasms requires better cystoscopic sampling. *J Urol.* 2002;167:2404-7. PMID: 11992046
- 5 Richterstetter M, Wullich B, Amann K, Haeberle L, Engehausen DG, Goebell PJ, et al. The value of extended transurethral resection of bladder tumour (TURBT) in the treatment of bladder cancer. *BJU Int.* 2012;110:E76-9. PMID: 22313727.
- 6 Kawada T, Ebihara K, Suzuki T, Imai K, Yamanaka H. A new technique for transurethral resection of bladder tumors: rotational tumor resection using a new arched electrode. *J Urol.* 1997;157:2225-6. PMID: 9146621.
- 7 Ukai R, Kawashita E, Ikeda H. A new technique for transurethral resection of superficial bladder tumor in 1 piece. *J Urol.* 2000;163:878-9. PMID: 10687997.
- 8 Saito S. Transurethral en bloc resection of bladder tumors. *J Urol.* 2001;166:2148-50. PMID: 11696724.
- 9 Lodde M, Lusuardi L, Palermo S, Signorello D, Maier K, Hohenfellner R, et al. En bloc transurethral resection of bladder tumors: use and limits. *Urology.* 2003;62:1089-91. PMID: 14665361.
- 10 Naselli A, Introini C, Germinale F, Spina B, Puppo P. En bloc transurethral resection of bladder lesions: a trick to retrieve specimens up to 4.5 cm. *BJU Int.* 2012;109:960-3. PMID: 22360804.
- 11 Maurice MJ, Vricella GJ, MacLennan G, Buehner P, Ponsky LE. Endoscopic snare resection of bladder tumors: evaluation of an alternative technique for bladder tumor resection. *J Endourol.* 2012;26:614-7. PMID: 22390750.
- 12 Oyama T, Tomori A, Hotta K, Morita S, Kominato K, Tanaka M, et al. Endoscopic submucosal dissection of early esophageal cancer. *Clin Gastroenterol Hepatol.* 2005;3:S67-70. PMID: 16013002.
- 13 Kakushima N, Fujishiro M. Endoscopic submucosal dissection for gastrointestinal neoplasms. *World J Gastroenterol.* 2008;14:2962-7. PMID: 18494043.
- 14 Mariappan P, Zachou A, Grigor KM, Edinburgh Uro-Oncology G. Detrusor muscle in the first, apparently complete transurethral resection of bladder tumour specimen is a surrogate marker of resection quality, predicts risk of early recurrence, and is dependent on operator experience. *Eur Urol.* 2010;57:843-9. PMID: 19524354.
- 15 Nieder AM, Meinbach DS, Kim SS, Soloway MS. Transurethral bladder tumor resection: intraoperative and postoperative complications in a residency setting. *J Urol.* 2005;174: 2307-9. PMID: 16280830.
- 16 Yamamoto H, Yahagi N, Oyama T, Gotoda T, Doi T, Hirasaki S, et al. Usefulness and safety of 0.4% sodium hyaluronate solution as a submucosal fluid "cushion" in endoscopic resection for gastric neoplasms: a prospective multicenter trial. *Gastrointest Endosc.* 2008;67:830-9. PMID: 18155216.
- 17 Hirasaki S, Kozu T, Yamamoto H, Sano Y, Yahagi N, Oyama T, et al. Usefulness and safety of 0.4% sodium hyaluronate solution as a submucosal fluid "cushion" for endoscopic resection of colorectal mucosal neoplasms: a prospective multi-center open-label trial. *BMC Gastroenterol.* 2009;9:1. PMID: 19128517.
- 18 Hakenberg OW, Linne C, Manseck A, Wirth MP. Bladder wall thickness in normal adults and men with mild lower urinary tract symptoms and benign prostatic enlargement. *Neurourol Urodyn.* 2000;19:585-93. PMID: 11002301.
- 19 Nylund K, Hausken T, Odegaard S, Eide GE, Gilja OH. Gastrointestinal wall thickness measured with transabdominal ultrasonography and its relationship to demographic factors in healthy subjects. *Ultraschall Med.* 2012;33:E225-32. PMID: 22504939.
- 20 Ukai R, Hashimoto K, Iwasa T, Nakayama H. Transurethral resection in one piece (TURBO) is an accurate tool for pathological staging of bladder tumor. *Int J Urol.* 2010;17:708-14. PMID: 20546051
- 21 Beaghtler M, Grasso M, 3rd. Flexible cystoscopic bladder biopsies: a technique for outpatient evaluation of the lower urinary tract urothelium. *Urology.* 1994;44:756-9. PMID: 7974952.
- 22 Muraishi O, Mitsu S, Suzuki K, Koshimizu T, Tokue A. A technique for resection of small bladder tumors using a flexible cystoscope on an outpatient basis: bladder tumor resection with newly designed hot cup forceps. *J Urol.* 2001;166:1817-9. PMID: 11586231.
- 23 Heney NM, Ahmed S, Flanagan MJ, Frable W, Corder MP, Hafermann MD, et al. Superficial bladder cancer: progression and recurrence. *J Urol.* 1983;130:1083-6. PMID: 6644886.
- 24 El-Abbady AA, Shoukry MS, Hanno AG, Younis LK, Abdel-Rahman M. Repeated transurethral resection of recurrent superficial bladder tumors--does it affect the spread and stage of the tumor? *Scand J Urol Nephrol.* 2002;36:60-4. PMID: 12002360.
- 25 Matsushita M, Hajiro K, Okazaki K, Takakuwa H. Endoscopic mucosal resection of gastric tumors located in the lesser curvature of the upper third of the stomach. *Gastrointest Endosc.* 1997;45:512-5. PMID: 9199911.
- 26 Ohkuwa M, Hosokawa K, Boku N, Ohtu A, Tajiri H, Yoshida S. New endoscopic treatment for intramucosal gastric tumors using an insulated-tip diathermic knife. *Endoscopy.* 2001;33:221-6. PMID: 11293753.
- 27 Ono H, Kondo H, Gotoda T, Shirao K, Yamaguchi H, Saito D, et al. Endoscopic mucosal resection for treatment of early gastric cancer. *Gut.* 2001;48:225-9. PMID: 11156645.
- 28 Yamamoto H, Kawata H, Sunada K, Sasaki A, Nakazawa K, Miyata T, et al. Successful en-bloc resection of large superficial tumors in the stomach and colon using sodium hyaluronate and small-caliber-tip transparent hood. *Endoscopy.* 2003;35:690-4. PMID: 12929067.
- 29 Rana A, Rashwan HM, West Of Stow J, Ng PE, Chisholm GD. Air insufflation versus water irrigation during flexible cystoscopy: a prospective randomized study. *Br J Urol.* 1994;74:311-4. PMID: 7953261.
- 30 Ciudin A, Diaconu MG, Gosalbez D, Peri L, Garcia-Cruz E, Franco A, et al. Air cystoscopy is superior to water cystoscopy for the diagnosis of patients with active hematuria. *J Urol.* 2013;190:2097-101. PMID: 23810642.