

Wart with Depigmented Halo and Generalized Vitiligo

Takamichi Ito,*† Yuichi Yoshida,* Koji Adachi,* Masutaka Furue† and Osamu Yamamoto*

**Division of Dermatology, Department of Medicine of Sensory and Motor Organs, School of Medicine, Tottori University Faculty of Medicine, Yonago 683-8503, Japan and †Department of Dermatology, Graduate School of Medical Sciences, Kyushu University, Fukuoka 812-8582, Japan*

Depigmented haloes sometimes appear around melanocytic tumors or non-melanocytic tumors, but coexistence of warts and depigmented haloes is extremely rare. We report here an unusual case of warts accompanied by depigmented haloes and subsequently-triggered generalized vitiligo. A 55-year-old Japanese man presented with a 3-year history of brown nodules on the back, upper eyelid and dorsum of the left hand. Depigmented haloes appeared around the nodules and then gradually spread over a wide area, resulting in the development of generalized vitiligo. He had no history of antecedent treatment for these lesions before consultation. Histopathologically, the lesion showed papillomatosis and hyperkeratosis with lymphocytic exocytosis into the epidermis, which compatible to warts. Based on these clinical and histopathologic findings, a diagnosis of warts with depigmented halo and subsequently-triggered generalized vitiligo was made. None of the warts had resolved spontaneously after the appearance of haloes, and the depigmented haloes and generalized vitiligo remain unchanged.

Key words: depigmented halo; verruca; vitiligo; wart

Depigmented haloes sometimes appear around melanocytic tumors such as melanocytic nevi and malignant melanomas. Although there have been sporadic patient reports on this phenomenon in non-melanocytic lesions, coexistence of warts and depigmented haloes is extremely rare. We report here an unusual case of warts accompanied by depigmented haloes and subsequently-triggered generalized vitiligo.

Patient Report

A 55-year-old Japanese man presented with a 3-year history of brown nodules. He had felt pruritus in the nodules 3 weeks before consultation. Depigmented haloes appeared around the nodules and then gradually spread over a wide area, resulting in the development of generalized vitiligo. He had no history of autoimmune diseases and family history of vitiligo. Physical examination revealed a relatively elevated, flat-topped verrucous nodule

on the left upper eyelid. It was 7 mm in size and the surface was papillomatous (Fig. 1). Results of routine laboratory studies were unremarkable. Dermoscopic examination revealed exophytic papillary structures with hyperkeratosis and dotted vessels in the tops of dermal papillae. Similar nodules were observed on the left face, upper part of the back and dorsum of the left hand. Most of the nodules were accompanied by depigmented haloes. Generalized vitiligo was also seen (Fig. 2). He underwent skin biopsy of the verrucous nodule with a depigmented halo on the dorsum of the left hand as a representative lesion. Histopathologically, the lesion showed papillomatosis and hyperkeratosis with lymphocytic exocytoses into the epidermis. In addition, there were superficial lymphocytic infiltrate in the dermis. Based on these clinical and histopathologic findings, a diagnosis of warts with depigmented halo and subsequently-triggered generalized vitiligo was made. None of the warts had resolved spontaneously after the appearance of haloes. Residual

warts were treated with cryotherapy, and most of them consequently showed involution. However, the depigmented haloes and generalized vitiligo remain unchanged during follow-up period of 6 months.

Discussion

Some non-melanotic lesions are known to be associated with depigmented haloes, but warts with haloes are extremely rare (Berman, 1977); there have been only 2 cases in a previous literature. Berman reported that depigmented haloes developed around involuting flat warts in 2 patients whose warts were treated with a 6% salicylic acid-propylene glycol formulation (Berman, 1977). In those patients, all of the warts disappeared soon after the appearance of depigmented haloes, but generalized vitiligo was not found.

There are 2 different points between our patient and previous ones (Berman, 1977); the presence of antecedent treatment and generalized vitiligo. Berman used salicylic acid-propylene glycol gel for treatment of the warts. Some topical agents, such as imiquimod and diphenylcyclopropanone, have been reported to induce depigmented vitiligo (Serrão et al., 2008; Oh et al., 2012). These agents are thought to activate host immune reactions. Although Berman confirmed that the gel did not in-

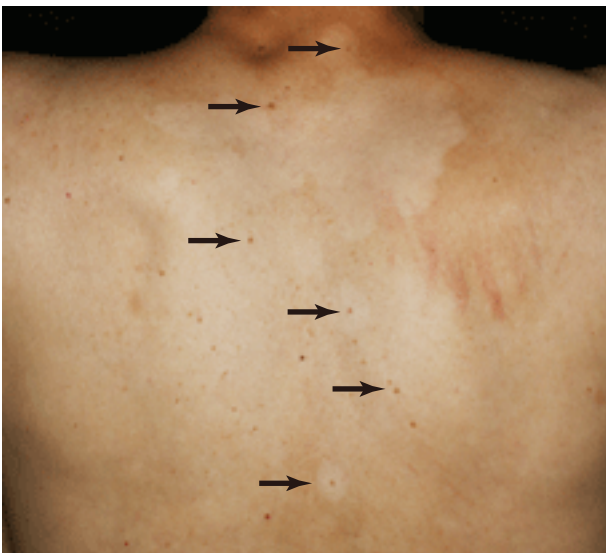

Fig. 2. Many verrucous nodules with depigmented haloes and generalized vitiligo on the upper part of the back (arrows).

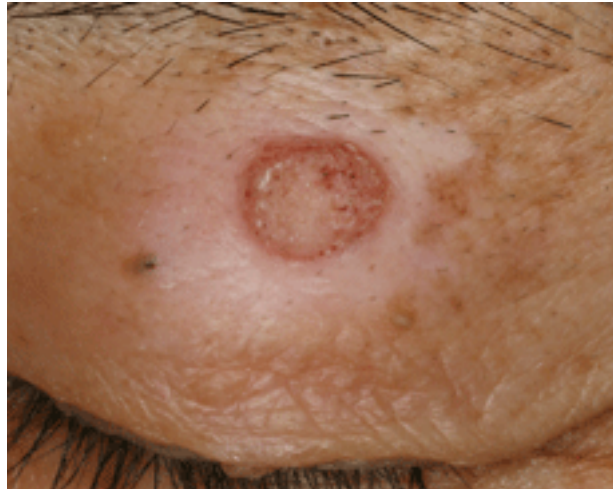


Fig. 1. A verrucous nodule with a depigmented halo on the left upper eyelid.

duce depigmentation in some healthy people, there remains the possibility of an association between the gel and depigmentation. However, no antecedent topical agent was used in our patient.

Pathogenesis of the halo phenomenon is still unclear. However, it seems that vitiligo lesion on the back in our patient is composed of multiple depigmented haloes. Because a large number of lymphocytes had infiltrated into the verrucous lesion in our biopsied specimen, both depigmented haloes and generalized vitiligo might have been elicited by host reaction, leading to the decrease of melanocytes. It is of interest that our patient had generalized vitiligo that spread after inflammation of warts.

References

- 1 Berman A. Depigmented haloes associated with the involution of flat warts. *Brit J Dermatol* 1977;97:263–265.
- 2 Oh YJ, Shin MK, Lee MH. Narrow-band ultraviolet B treatment for dyphenylcyclopropanone-induced vitiliginous lesions. *Acta Derm Venereol* 2012;92:102–103.
- 3 Serrão VV, Páris FR, Feio AB. Genital vitiligo-like depigmentation following use of imiquimod 5% cream. *Eur J Dermatol* 2008;18:342–343.

Received October 25, 2012; accepted October 29, 2012

Corresponding author: Takamichi Ito, MD