

# A Case of the Bilateral Duplicate Palmaris Longus Muscles Coupled with the Palmaris Profundus Muscle

Yuichi Takanashi, Masaki Eda, Toshiyuki Kaidoh\* and Takao Inoué

*Division of Morphological Analysis, Department of Anatomy, School of Medicine, Tottori University Faculty of Medicine, Yonago 683-8503, Japan and \*Division of Medical Morphology, Department of Anatomy, School of Medicine, Tottori University Faculty of Medicine, Yonago 683-8503, Japan*

**The palmaris longus muscle is one of the most variable muscles in human anatomy. During a routine anatomical dissection for medical students at Tottori University, we found duplicate palmaris longus muscles in the bilateral forearms together with the palmaris profundus muscle in the right forearm. The bilateral aberrant palmaris longus muscles were observed at the ulnar side of the palmaris longus muscle and their distal tendons were attached to the flexor retinaculum. The palmaris profundus muscle found in the right forearm was located at the radial side of the flexor digitorum superficialis muscle. The proximal tendon was originated from the anterior surface in the middle of the radius, while the distal tendon coursed radial to the median nerve through the carpal tunnel, finally inserting into the distal part of the flexor retinaculum. Both the palmaris longus and aberrant palmaris longus muscles were innervated by the median nerve. The palmaris profundus muscle was presumably supplied by the median nerve.**

**Key words:** cadaver; forearm; regional anatomy; skeletal muscle

The palmaris longus muscle (PL) is located in the superficial layer of the anterior surface of the forearm. It has a small belly arising from the medial epicondyle of the humerus, and its long thin tendon inserts into the palmar aponeurosis in the hand. The muscle is one of the most variable muscles in the human body (Takafuji et al., 1985). During an anatomical dissection for medical students at Tottori University in 2011, we found a pair of the duplicate PL in the bilateral forearms. Furthermore, the palmaris profundus muscle (PP), which is not usually exist, was found in the right forearm. Although the duplicate PL is frequently reported (Reimann et al., 1944; Hojo, 1976; Kimura et al., 1979; Xue et al., 1998; Zeybek et al., 1998; Kawashima et al., 2002), it is rarely seen in bilateral forearms. In addition, there are no reports on the bilateral duplicate PL

coupled with the PP. In this paper, we describe myological findings and innervation of this rare case.

## Materials and Methods

Anomaly of the PL was noticed on both sides of a 57-year-old Japanese male cadaver. We observed closely the origin and insertion of the muscles, finely dissected the region of interest, and examined muscle shape and nerve supplies macroscopically, and photographed. We also measured the size of the muscles and tendons using a vernier caliper. The length of a muscle belly was measured between the origin (medial epicondyle) and the most distal part of the muscle-tendon border. The length of PL tendon was measured from the most distal part of

---

Abbreviations: FCR, flexor carpi radialis muscle; FCU, flexor carpi ulnaris muscle; FDS, flexor digitorum superficialis muscle; PL, palmaris longus muscle; PP, palmaris profundus muscle; PT, pronator teres muscle

the muscle-tendon border to the base of palmar aponeurosis, whereas that of aberrant PL was done from the identical point to the attachment to the flexor retinaculum. The width of muscle belly was measured at the maximum width. The width and thickness of the both PL and aberrant PL were measured at the midpoint of the entire length of the tendon.

### Results

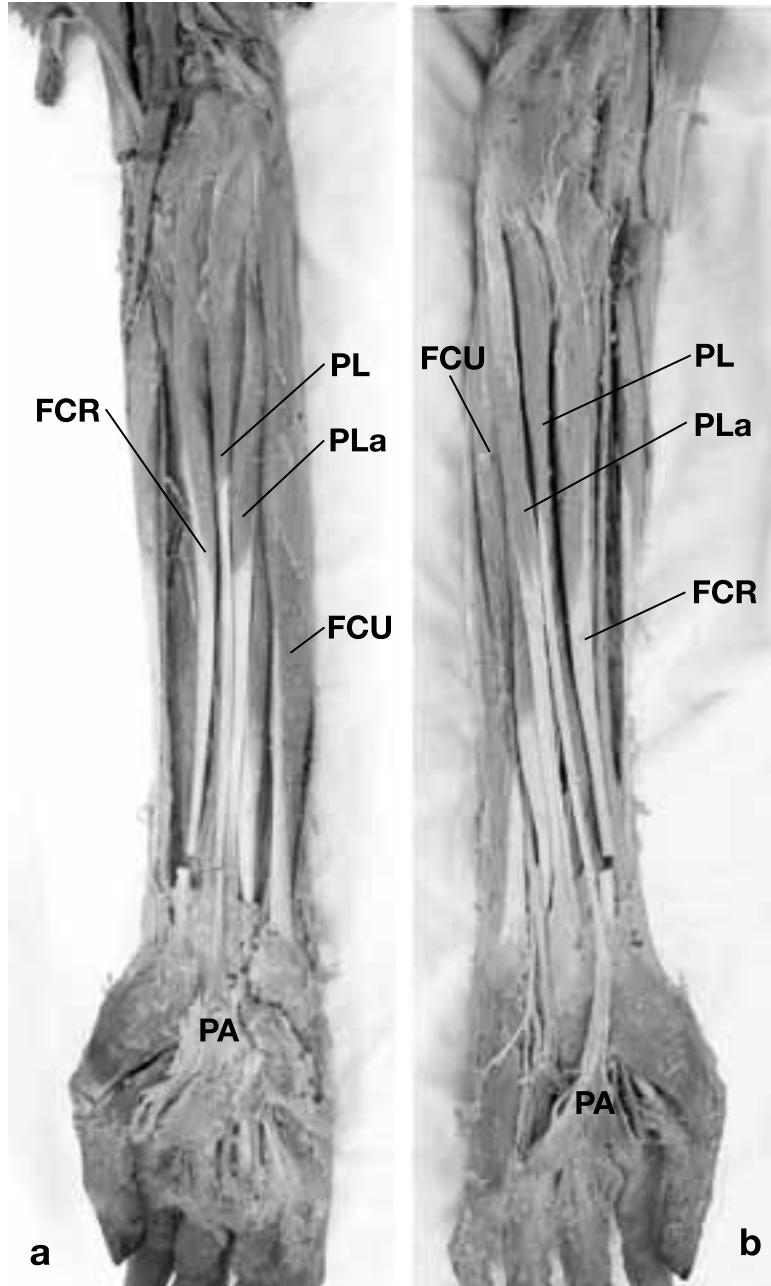
The duplicate PL and their nerve supply found in the bilateral forearms are shown in Figs. 1 and 2, respectively. Their measurements, myological findings and nerve innervations are summarized in Table 1. The PP in the right forearm is shown in Fig. 3. No other muscular anomaly was recognized in the body.

#### **Duplicate PL in the right forearm**

The aberrant PL was found ulnar to the PL (Fig. 1a). The bellies and tendons of both the aberrant PL and PL were closely apposed with each other. The duplicate PL arose from a common tendinous origin of flexor muscles [PL, flexor carpi radialis muscle (FCR), flexor carpi ulnaris muscle (FCU), pronator teres muscle (PT) and a part of the flexor digitorum superficialis muscle (FDS)] at the medial epicondyle of the humerus.

In the PL, the muscle belly measuring 110 mm in length and 12.6 mm in width, was followed by a long tendon distally at the middle of the forearm. The tendon coursed over the flexor retinaculum, finally inserting into the palmar aponeurosis (Table 1).

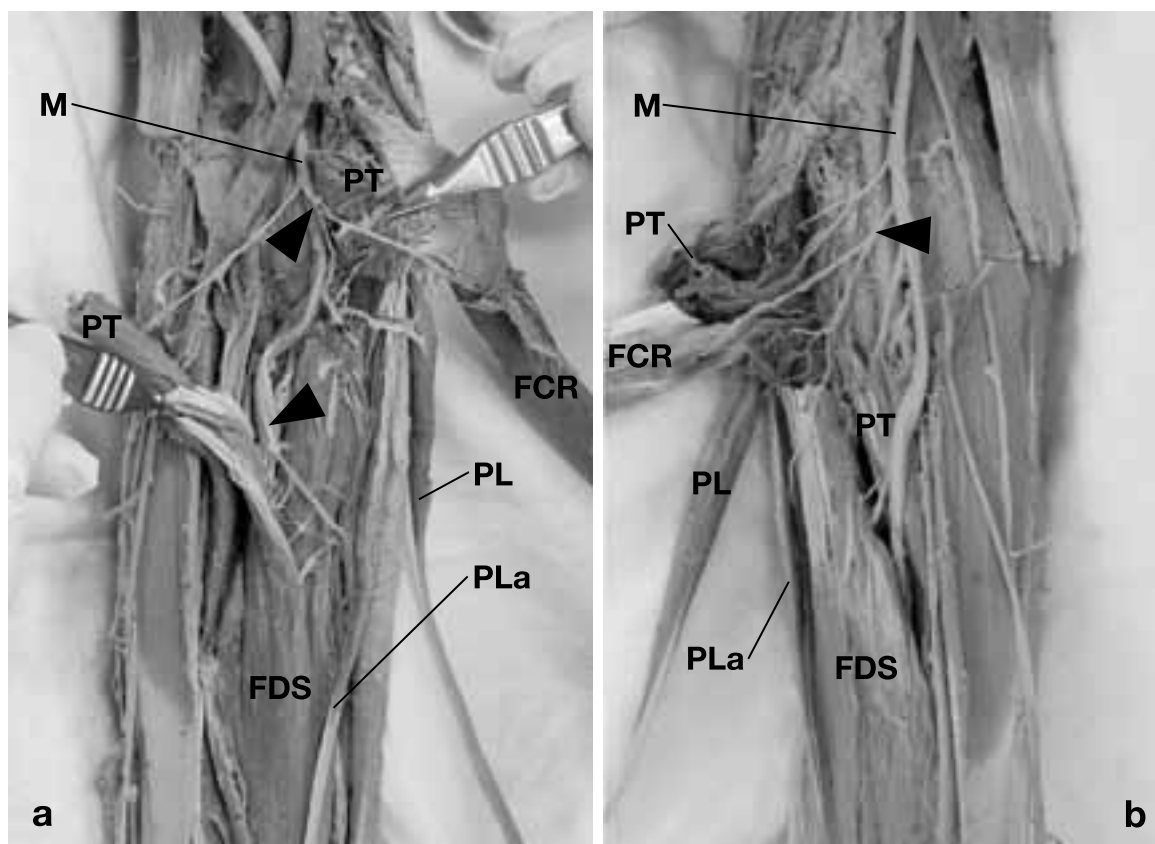
The morphology of the aberrant PL was quite similar to that of the PL. The muscle belly measuring 135 mm in length and 10 mm in width was



**Fig. 1.** Photographs of superficial flexor muscles of the forearm. Note PLa between PL and FCU. **a:** right side, **b:** left side. FCR, flexor carpi radialis muscle; FCU, flexor carpi ulnaris muscle; PA, palmar aponeurosis; PL, palmaris longus muscle; PLa, aberrant palmaris longus muscle.

followed by the tendon distally at the middle of forearm, and finally inserting into the flexor retinaculum (Table 1).

Both the PL and aberrant PL were innervated by branches of the median nerve in the proximal third of the forearm (Fig. 2a). The branches to the FCR, PL and FDS arose as a common trunk from



**Fig. 2.** Photographs showing the median nerve and its branches to flexor muscles. The belly of the pronator teres is cut and opened for the demonstration of the innervation. Arrowheads show the common trunk of the median nerve to the PL and PLa. **a:** right side, **b:** left side. FCR, flexor carpi radialis muscle; FDS, flexor digitorum superficialis muscle; M, median nerve; PL, palmaris longus muscle; PLa, aberrant palmaris longus muscle; PT, pronator teres muscle.

the median nerve, whereas those to the aberrant PL and FDS arose as another common trunk which branched distally.

#### ***Duplicate PL in the left forearm***

The morphological findings of the duplicate PL in the left forearm are fundamentally identical to those in the right forearm.

The aberrant PL was also found ulnar to the PL (Fig. 1b). The bellies and tendons of both the aberrant PL and PL were closely apposed with each other. The duplicate PL arose from a common tendinous origin of flexor muscles (PL, FCR, FCU, PT and a part of the FDS) at the medial epicondyle of the humerus.

In the PL, the muscle belly measuring 130 mm in length and 10 mm in width was followed

by a long tendon distally at the middle of the forearm. The tendon coursed over the flexor retinaculum, finally inserting into the palmar aponeurosis (Table 1).

The morphology of the aberrant PL was quite similar to that of the PL. The muscle belly measuring 145 mm in length and 8.3 mm in width was followed by the tendon distally at the middle of forearm, and finally inserting into the flexor retinaculum (Table 1).

Similarly to the right forearm, both the PL and aberrant PL were innervated by branches of the median nerve in the proximal third of the forearm (Fig. 2b). However, the ramification of the branch was different. The branches to the FCR, PL, aberrant PL and FDS arose as a proximal common trunk from the median nerve, and another single branch to FDS arose distally from the median nerve.

**Table 1. Summary of PL and aberrant PL**

			PL		Aberrant PL	
			Right	Left	Right	Left
Muscle belly	Length	(mm)	110.0	130.0	135.0	145.0
	Width	(mm)	12.6	10.0	10.0	8.3
Tendon	Length	(mm)	155.0	140.0	105.0	100.0
	Width	(mm)	3.8	3.8	6.2	6.2
	Thickness	(mm)	1.1	1.1	0.6	0.7
Origin			Medial epicondyle	Medial epicondyle	Medial epicondyle	Medial epicondyle
Insertion			Palmar aponeurosis	Palmar aponeurosis	Flexor retinaculum	Flexor retinaculum
Innervation			Median nerve	Median nerve	Median nerve	Median nerve

PL, palmaris longus muscle.

### ***PP in the right forearm***

The PP in the right forearm was located at the radial side of the middle part of FDS. It was spindle in shape with slender tendons on both ends. The proximal tendon was apparently independent to the radial head of the FDS and originated from the anterior surface in the middle of the radius. The muscle belly measured 77 mm in length. The distal tendon measuring 45 mm in length coursed radial to the median nerve under the flexor retinaculum. It passed through the carpal tunnel together with the median nerve, and finally inserted into the distal part of flexor retinaculum (Fig. 3). Since the PP coursed in the vicinity of the median nerve, the muscle was presumably supplied by the median nerve. The branch to the muscle could not be macroscopically demonstrated.

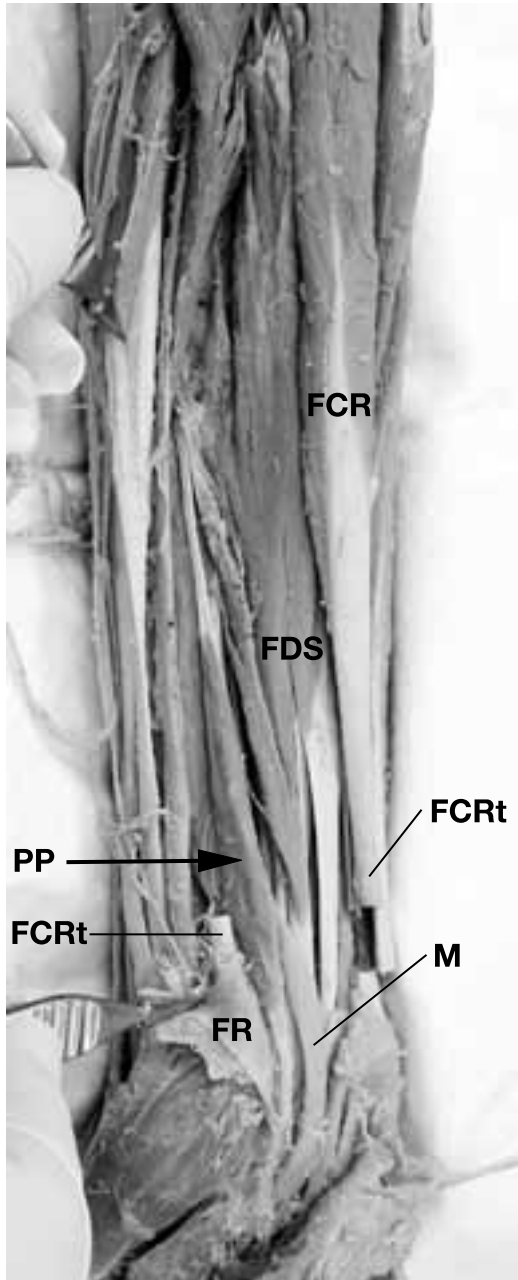
### **Discussion**

The variation of the PL was classified by Reimann et al. (1944) as follows: complete agenesis, variation in the location and form of the fleshy portion, aberrancy in the attachment at either extremity, duplication or triplication, accessory slips or substitutions of similar form or position. In particular, duplicate PL has been frequently reported (Reimann et al., 1944; Hojo, 1976; Kimura et al., 1979; Xue et al., 1998; Zeybek et al., 1998; Kawashima et al., 2002). The occurrence of duplicate PL in Japanese is 1.9%

(Koganei et al., 1903), 2.1% (Adachi, 1910), 2.5% (Sato et al., 1974), whereas 3.1% in Russians (Gruber, 1868) and 0.8% in Americans (Reimann et al., 1944).

Most of the duplicate PL thus far reported were unilateral. As far as we know, there was only one report of the duplicate PL in both forearms (Kimura et al., 1979). As for the occurrence of the aberrant PL in the duplicated PL, it is mostly located at the ulnar side of PL as observed in the present study (Xue et al., 1998), but occasionally at the radial side (Kawashima et al., 2002). The aberrant PL is innervated by the median nerve as was observed in the present study (Kimura et al., 1979; Takafuji et al., 1985; Xue et al., 1998; Kawashima et al., 2002), but occasionally doubly innervated both by the median and ulnar nerve (Xue et al., 1998).

The PP is another case of the anomaly of the PL. It originates from the anterior surface of the radius terminating to the flexor retinaculum of the deeper layer of the palmar aponeurosis (Reimann et al., 1944). Yoshida et al. (1983) observed variations of the deep flexor group of the antebrachial muscles and classified them into four types. Our case corresponds to the type 2 (palmaris profundus longus muscle) of their classification. The present case is also analogous to that reported by Stark et al. (2010). Humphry (1872) proposed the idea that the superficial layers of the forearm flexor muscles are derived from radial, intermediate, and ulnar sectors in the ventral matrix of the elbow (Howell, 1936a). According to this hypothesis, the PT and FCR are differentiated from the radial sector, the FCU from



**Fig. 3.** Photograph of the anterior side of the right forearm, showing the palmaris profundus muscle (PP with arrow). The flexor retinaculum is transected and turned over. The tendon of the flexor carpi radialis is cut for the demonstration of the distal tendon of the palmaris profundus muscle. FCR, flexor carpi radialis muscle; FDS, flexor digitorum superficialis muscle; FR, flexor retinaculum; PP, palmaris profundus muscle.

the ulnar sector, and the PL from the intermediate sector. Straus (1942) pointed out that the aberrant PL is differentiated from the radial or ulnar sectors.

As for the PP, Takisawa et al. (1979) considered that the PP is derived from the radial sector.

From a viewpoint of phylogeny, the PL is absent in the lowest class of mammals such as Monotremata (Platypus) (Howell, 1936b). With the progress of the locomotion in hands, the palmar aponeurosis has appeared. Although the PL inserts to the aponeurosis in the human, the final insertion is different in animals: the proximal phalanx in the unau (Humphry, 1869), kinkajou and genet (Parsons, 1898); the flexor retinaculum in the tamandua (Windle and Parsons, 1899); both the palmar aponeurosis and flexor retinaculum in the chimpanzee and cynocephalus (Champneys, 1871). Since the aberrant PL and PP insert into the flexor retinaculum, these muscles are considered to be a kind of atavism.

The PL and PP are of clinical importance from viewpoints of tendon grafts and carpal tunnel syndrome, respectively. The PL is frequently used as a donor tendon for ligament reconstruction including elbow, wrist and so on (Nestor et al., 1992; Ogunro, 2007; Whitaker et al., 2008). Although the duplicate PL is not so frequently occurred as mentioned above, it will provide a useful grafts in tendon surgery when found in patients. Since the distal tendon of the PP courses in the vicinity of the median nerve as seen in this study, it sometimes compresses the median nerve, causing a carpal tunnel syndrome (Floyd et al., 1990; Server et al., 1995; Miyoshi et al., 2000). It is interesting that the PP reflecting the old phylogenetic pattern occasionally cause a carpal tunnel syndrome. It is also important to pay a special attention of the presence or absence of the PP in this syndrome.

### References

- 1 Adachi B. Beiträge zur anatomie der Japaner. XII Die Statistik der Muskelvarietäten. *Z Morphol Anthropol* 1910;12:261–312.
- 2 Champneys F. The muscles and nerves of a chimpanzee (*trogodytes niger*) and a cynocephalus *anubis*. *J Anat Physiol* 1871;6:176–211.
- 3 Floyd T, Burger RS, Sciaroni CA. Bilateral palmaris profundus causing bilateral carpal tunnel syndrome. *J Hand Surg Am* 1990;15:364–366.

- 4 Gruber W. Über die varietäten des musculus an palmaris longus. Mem l'Acad Imp Sci St Petersburg 1868; S711:1–26.
- 5 Hojo T. A case of the duplicate palmaris longus muscle. Acta Anat Nippon 1976;51:422–425.
- 6 Howell AB. Phylogeny of the distal musculature of the pectoral appendage. J Morphol 1936a;60:287–315.
- 7 Howell AB. The musculature of antebrachium and manus in the platypus. Am J Anat 1936b;59:425–432.
- 8 Humphry. The myology of the limbs of the unau, the ai, the two-toed anteater, and the pangolin. J Anat Physiol 1869;4:17–78.
- 9 Humphry. On the disposition of muscles in vertebrate animals. J Anat Physiol 1872;6:293–376.
- 10 Kawashima T, Kikushima S, Yokota E, Ohkubo F, Yamada Y, Sato F, et al. A case of an accessory palmaris longus muscle and a duplicate palmaris longus muscle with special reference to their nerve supply—morphologic significance of a common innervation trunk. Okajimas Folia Anat Jpn 2002;79:75–81.
- 11 Kimura K, Konishi M, Takahashi Y. A case of the duplicate palmaris longus muscle. Boei Ikadaigakko Zasshi 1979;4:57–59 (in Japanese with English abstract).
- 12 Koganei Y, Arai H, Shikinami J. Varietätenstatistik der musculn. Tokyo Igakkai Zasshi 1903;17:127–131 (in Japanese with German abstract).
- 13 Miyoshi S, Kanaya F, Futenma C, Ibaraki K. Carpal tunnel syndrome caused by palmaris profunda. Seikeigeka To Saigaijeka 2000;49:877–879 (in Japanese with English abstract).
- 14 Nestor BJ, O'Driscoll SW, Morrey BF. Ligamentous reconstruction for posterolateral rotatory instability of the elbow. J Bone Joint Surg Am 1992;74:1235–1241.
- 15 Ogunro O. Dynamic stabilization of chronic scapholunate dissociation with palmaris longus transfer: a new technique. Tech Hand Up Extrem Surg 2007;11:241–245.
- 16 Parsons FG. The muscles of mammals, with special relation to human myology. J Anat Physiol 1898;32:721–752.
- 17 Reimann AF, Dasaler EH, Anson BJ, Beaton LE. The palmaris longus muscle and tendon. A study of 1600 extremities. Anat Rec 1944;89:495–505.
- 18 Sato Y, Takeuchi R, Umeno K, Chen S, Takafuji T. A contribution to the study of the M palmaris longus. Acta Anat Nippon 1974;19:318–319.
- 19 Server F, Miralles RC, Galcerá DC. Carpal tunnel syndrome caused by an anomalous palmaris profundus tendon. J Anat 1995;187:247–248.
- 20 Stark ME, Dell MM, Wisco JJ. A variation of the palmaris profundus muscle. IJAV 2010;3:36–38.
- 21 Straus WL. The homologies of the forearm flexors: urodeles, lizards, mammals. Am J Anat 1942;70:281–316.
- 22 Takafuji T, Azuma S, Tozawa T, Kawashima T, Takeuchi R, Sato Y. A morphological study on the human palmaris longus muscle. Kyorin Igakkai Zasshi 1985;16:341–353 (in Japanese with English abstract).
- 23 Takisawa A, Fujimaki N, Jinguji Y. [A rare case of m. palmaris profundus (author's transl)]. Kaibogaku Zasshi 1979;54:136–139 (in Japanese).
- 24 Whitaker I, Cairns S, Josty I. The palmaris longus tendon weave: a novel method of reconstructing the transverse carpal ligament. Plast Reconstr Surg 2008;122:227–228.
- 25 Windle BCA, Parsons FG. On the myology of the edentata. Proc Zool Soc Lond 1899;69:314–339.
- 26 Xue H, Yang C, Kawate T, Atsumi S. A case of the duplicate palmaris longus muscle. Yamanashi Ikadaigaku Zasshi 1998;13:127–131 (in Japanese with English abstract).
- 27 Yoshida Y, Yasutaka S, Seki Y. Studies on the flexor carpi radialis profundus and palmaris profundus muscle in man. Acta Anat Nippon 1983;58:59–67 (in Japanese with English abstract).
- 28 Zeybek A, Gurunluoglu R, Cavdar S, Bayramicli M. A clinical reminder: a palmaris longus muscle variation. Ann Plast Surg 1998;41:224–225.

*Received September 27, 2012; accepted October 26, 2012*

*Corresponding author: Yuichi Takanashi*