

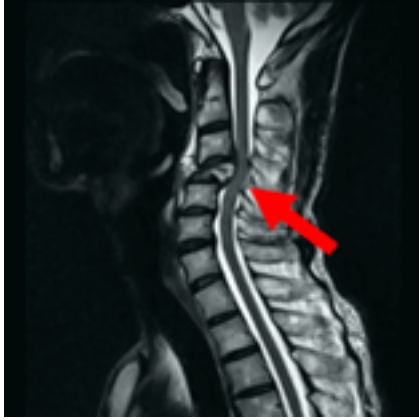

Fig. 4. Magnetic resonance imaging shows a pathological fracture in the cervical vertebrae, stricture of the vertebral canal and the oppression of the spinal nerve (arrow).

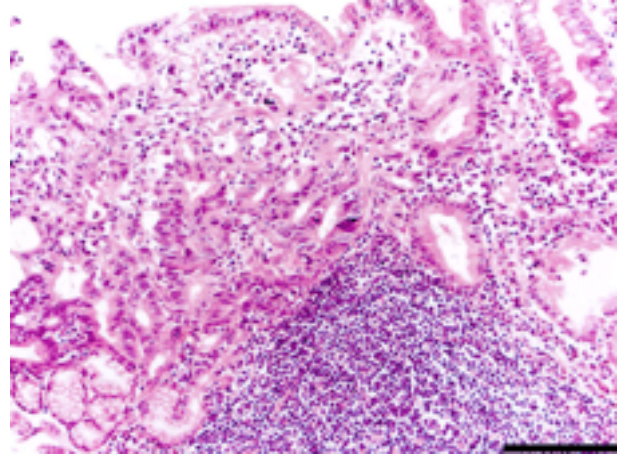


Fig. 5. A moderately differentiated type of tubular adenocarcinoma is observed in a biopsy specimen of gastric adenocarcinoma of the patient (hematoxylin and eosin stain). Bar =100 μ m.

ing his history of having a 75% gastrectomy 6 years previous due to gastric adenocarcinoma, we histopathologically examined biopsy specimens from the gastric region and cervical vertebrae, and observed the moderately differentiated type of tubular adenocarcinoma in all specimens (Fig. 5). We also examined biopsy specimens of the stomach, mandible and cervical vertebrae immunohistochemically. The results of the staining were the same in all specimens: positive for cytokeratin AE1/3, EMA, CK7 (Fig. 6a), CA19-9 (Fig. 6b) and CEA (Fig. 6c) and negative for cytokeratin 20, CA125 and PSA. Ultimately, we diagnosed his disease as metastatic adenocarcinoma from gastric adenocarcinoma to the lung, cervical vertebrae and mandible. The metastasis spread throughout his whole body to the point where no further active treatment was possible. The patient was transferred to another facility, where he received palliative therapy. The progress of the tumor was rapid, and the patient died of pulmonary insufficiency 2 months later.

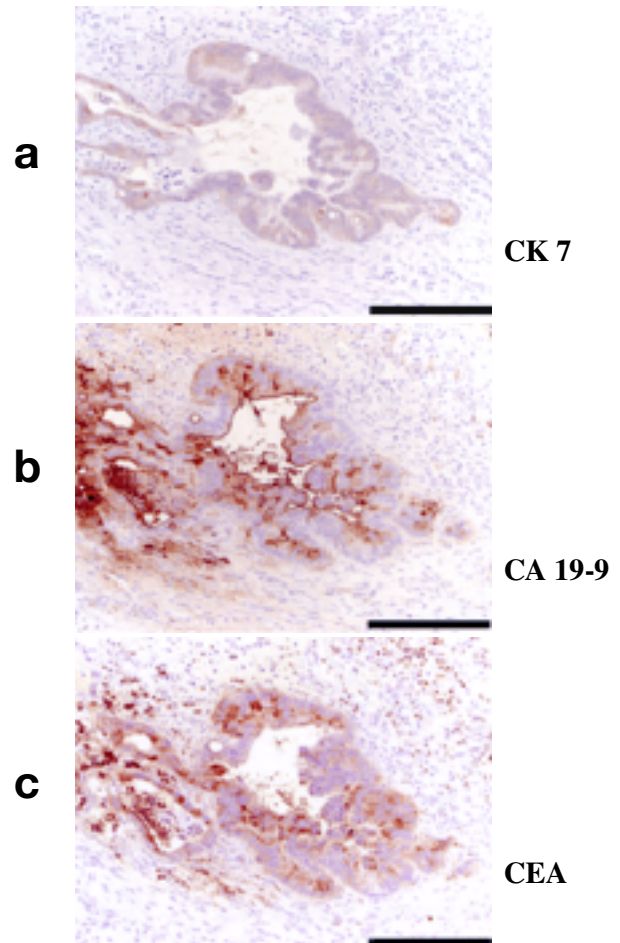


Fig. 6. Immunohistochemical detection of metastases to the mandible in the glandular epithelium on the biopsy specimen of mandibular ramus: positive staining for AE1/3, EMA, CK7 (a), CA19-9 (b) and CEA (c); and negative staining for CK 20, CA 125 and PSA. The results match those observed in the primary gastric adenocarcinoma. Bar =100 μ m.

Discussion

Of all oral carcinomas, about 80% are squamous cell carcinomas, followed by salivary gland carcinomas, malignant lymphomas, and metastatic tumors to the oral region with a decreasing incidence of about 10%, 4% and 1% (Meyer and Shklar, 1965; Chin et al., 1998; Vahatalo et al., 2000). The main characteristic of oral squamous cell carcinoma is ulcer formation, except for intraosseous carcinoma of the mandible, and diagnosis is relatively easy. But many metastatic tumors are adenocarcinomas (Handa et al., 1990) with no ulcer formation, and diagnosis of metastatic tumor can be difficult. Sometimes discriminating between carcinomas originating in the oral cavity and metastatic tumors originating elsewhere is difficult even when lesions show histopathologic features of squamous cell carcinoma. For diagnosis of metastatic tumors, Zegarelli et al. (1973) established the following criteria: i) the primary tumor elsewhere is proved clinically and pathologically; ii) metastatic and primary tumors are histologically similar; iii) no tumor existed on the metastatic site in the past; and iv) there is no direct invasion from any primary or other metastatic tumor in adjacent organs. Clausen and Poulsen (1963) established the following criteria for metastatic tumor: i) the lesion must be a true metastasis localized to the bone tissue, as distinguished from direct invasion by a primary tumor in relation to the jaw and/or from metastases to the surrounding soft tissue; ii) it must be a microscopically verified carcinoma; and iii) the location of the primary tumor must be known to ensure that researchers are dealing with a secondary lesion. When a tumor is a squamous cell carcinoma or adenocarcinoma, we should examine histopathologically whether the tumor is of oral origin or a metastasis. In our patient, the biopsy specimen inside the part of the left mandibular ramus proved that it was an adenocarcinoma: we needed to make a clear distinction between an adenocarcinoma of the salivary gland and a metastatic

tumor from gastric carcinoma.

The most frequent site of metastasis from gastric carcinoma is the liver. Our patient was not involved in hepatic metastasis from gastric carcinoma. But patients with metastasis to the oral region have been frequently without metastasis to the liver (Colombo et al., 2005). Tubular adenocarcinoma very rarely arises in the minor salivary gland. Adenocarcinoma originating from the minor salivary gland develops in the soft tissue of the oral cavity because the minor salivary gland exists in the submucosa. In this patient, adenocarcinoma occurred in the mandible, partially infiltrating the adjacent soft tissue. In consideration of these facts, his adenocarcinoma did not arise from the minor salivary gland but metastasized from gastric carcinoma to the mandible.

Furthermore, in immunohistochemical examination of the biopsy specimens of the stomach, mandible and cervical vertebrae, all specimens showed the same staining results: positive for cytokeratin AE1/3, EMA, CK7, CEA and CA19-9, and negative for cytokeratin 20, CA125 and PSA. These conditions agree with the criteria established by Zegarelli et al. (1973) and Clausen and Poulsen (1963). Therefore, we finally diagnosed his disease as metastatic adenocarcinoma from gastric carcinoma to the lung, cervical vertebrae and mandible. Our case is further proof that immunohistochemical examination is very useful when it is difficult to give a definite diagnosis (Alvarez-Alvarez et al., 2006).

The primary sites of metastasis to the oral region are the lungs (25.2%), kidneys (14.6%), uterus (12.6%) and stomach (11.7%) (Koizumi et al., 2004). Pancreatic carcinoma does not metastasize easily because it is aggressively lethal to the system well before it metastasizes to the oral region (Hirshberg et al., 1993). Gastric carcinoma is relatively well controllable with a high survival rate. This fact could increase the possibility of metastasis to the oral region.

In analyzing the period from initial diagnosis of the primary lesion to metastasis to the oral region, metastases to the jaw appeared on an

average of 39.5 months (Kataoka et al., 2003). In that study, 17 cases of metastases to the oral region were examined by dividing them into well- and poorly-controlled groups. The examination period ranged from 2 to 99 months (mean, about 50 months) in the well-controlled group, whereas the mean was about 15 months in the poorly-controlled group. Our patient's tumor took a comparatively long time to metastasize to the oral region because the primary lesion was well under control for 6 years. In the oral region, the jaw is a common location of metastasis with predilection for the mandible and molar area. As for the probable causes of the occurrence of metastasis, Nakagawa et al. (1991) explained that the pooling of blood in myeloid tissue of the mandible might contribute to the retention of disseminated tumor cells and that the inferior alveolar artery winds its way around the angle of the mandible and in the mental region which causes blood flow to slow down.

Sharp pain and paralysis in the mental region occur as initial symptoms when tumors metastasize to the mandible (Glaser et al., 1997). We should suspect mandibular metastasis when paralysis of the mental region is recognized (Osaki et al., 1978). In our patient, paralysis in the mental region appeared following sharp pain in the mandible. The paralysis hardly improved despite antibiotics, so we carried out the biopsy for definitive diagnosis. Because the molar area of the mandible is a region where metastatic tumors often develop, we should suspect malignant tumor when paralysis of the mental region persists.

In general, metastatic tumors of the oral region are a part of multiple distant metastases and the prognosis is extremely poor: most patients have a fatal outcome of metastasis from the primary tumor within 1 year (Nakagawa et al., 1991; Yajima and Miyazaki, 1999; Kuttan et al., 2006). In making a decision about treatment for metastatic tumor, we should synthetically evaluate clinical manifestations, stage of progress, presence of metastases to other organs and wishes of the patient. In this patient, multiple metastases had already developed extensively when metastatic tumor of the

mandible was confirmed. Based on his condition and quality of his life, palliative treatment was unavoidably selected for the oral lesion.

References

- 1 Alvarez-Alvarez C, Iglesias-Rodríguez B, Pazo-Irazu S, Delgado-Sánchez-Gracián C. Colonic adenocarcinoma with metastasis to the gingiva. *Med Oral Patol Oral Cir Bucal*. 2006;11:E85–87.
- 2 Chin A, Liang TS, Borislow AJ. Initial presentation of hepatocellular carcinoma as a mandibular mass. *Oral Surg Oral Med Oral Pathol* 1998;86:457–460.
- 3 Clausen F, Poulsen H. Metastatic carcinoma of the jaws. *Acta Pathol Microbiol Scand* 1963;57:361–374.
- 4 Colombo P, Tondulli L, Masci G, Muzza A, Rimassa L, Petrella D, et al. Oral ulcer as an exclusive sign of gastric cancer: report of a rare case. *BMC Cancer*. 2005;19:117.
- 5 Glaser C, Lang S, Pruckmayer M, Millesi W, Rasse M, Marosi C, et al. Clinical manifestations and diagnostic approach to metastatic cancer of the mandible. *Int J Oral Maxillofac Surg* 1997;26:365–368.
- 6 Handa K, Kohno M, Shingaki S, Nakajima T, Mori M. Carcinoma of the pancreas metastatic to the mandible: report of a case and a review of the Japanese literature. *Nippon Koku Geka Gakkai Zasshi* 1990;36:194–201 (in Japanese with English abstract).
- 7 Hirshberg A, Leibovich P, Buchner A. Metastases to the oral mucosa: analysis of 157 cases. *J Oral Pathol Med* 1993;22:385–390.
- 8 Kataoka S, Shibata M, Doi R, Onda M, Sudoh M, Ryoike K. A clinical study of 17 cases of malignant tumors metastatic to the mouth and jaws. *Nippon Koku Geka Gakkai Zasshi* 2003;49:566–569 (in Japanese with English abstract).
- 9 Koizumi K, Hayashido Y, Yoshioka Y, Hara J, Okamoto T. A case of carcinoma of sigmoid colon metastasizing to the maxillary gingival. *Nippon Koku Geka Gakkai Zasshi* 2004;50:396–399 (in Japanese with English abstract).
- 10 Kuttan NA, Flemming DK, Dane JN, Ang DB. Metastatic lesion of the anterior mandible with an occult primary: a case report. *Spec Care Dentist* 2006;26:76–80.
- 11 Meyer I, Shklar G. Malignant tumors metastatic to mouth and jaws. *Oral Surg Oral Med Oral Pathol* 1965;20:350–362.
- 12 Nakagawa K, Kumagai S, Kozima K, Imai K, Yamamoto E. Three cases of metastatic lung carcinoma to the oral cavity. *Nippon Koku Geka Gakkai Zasshi* 1991;37:1363–1371 (in Japanese with English abstract).
- 13 Osaki T, Ryoike K, Hamada T. Two cases of oral

- metastatic tumor (adenocarcinoma) and review of literature. *Nippon Koku Kagakukai Zasshi* 1978;27:173–185 (in Japanese).
- 14 Vahatalo K, Ekfors T, Syrjänen S. Adenocarcinoma of the pancreas metastatic to the mandible. *J Oral Maxillofac Surg* 2000;58:110–114.
- 15 Yajima M, Miyazaki T. Metastasis of gastric adenocarcinoma to the maxillary gingival: report of a case. *Nippon Koku Geka Gakkai Zasshi* 1999;50:497–499 (in Japanese with English abstract).
- 16 Zegarelli DJ, Tsukada Y, Pickren JW, Greene GW Jr. Metastatic tumor to the tongue. *Oral Surg Oral Med Oral Pathol* 1973;35:202–211.

Received March 10, 2008; accepted May 8, 2008

Corresponding author: Takayuki Tamura, DD