

Vascular Leiomyoma of the Nasal Cavity: Case Report and Review of the Literature

Mari Osaki, Mitsuhiko Osaki, Isamu Kodani, Hironobu Adachi, Itoji Shibata* and Hisao Ito

*Division of Organ Pathology, Department of Microbiology and Pathology, School of Medicine, Tottori University Faculty of Medicine, Yonago 683-8503 and *Shibata Otorhinolaryngology Clinic, Tottori 680-0862 Japan*

We reported a rare case of nasal vascular leiomyoma that developed in a 67-year-old man. The tumor showed characteristic histological findings with proliferation of smooth muscle cells intermingled with dilated venous vessels. Review of the literature indicated that nasal vascular leiomyoma is characterized by female predominance, occurrence in aged patients and nasal obstruction or pain as the primary symptom.

Key words: immunohistochemistry; nasal cavity; vascular leiomyoma

Leiomyomas are benign myogenic neoplasms that may occur wherever smooth muscle is present. According to Enzinger and Weiss (1995), who analyzed a total of 7,748 leiomyomas, 95% of the tumors occurred in the female genitalia (uterus), 3% in the skin, 0.9% in the gastrointestinal tract and the remainder in various sites. Leiomyomas are classified into 3 histological subtypes: vascular, nonvascular and epithelioid or leiomyoblastoma (Batsakis, 1979). Vascular leiomyoma is a relatively uncommon smooth muscle tumor rarely found in the neck and head area. Herein, we present a rare case of vascular leiomyoma developed in the nasal septum.

Patient Report

A 67-year-old man visited an otorhinolaryngology clinic in June 1999, with a 2-week history of left-sided nasal obstruction and intermittent bloody discharge. He had no other symptoms such as headache, pain or epistaxis. Physical examination revealed a round wide-based mass measuring 8 mm in diameter on the left nasal septum, covered with a dark reddish nasal mucous membrane. No teleangiectasis or bleeding was noted. He was followed up for about 6 months.

Thereafter, the tumor was completely excised with marginal normal nasal mucosa. Post-operative recovery was uneventful. The patient has shown no recurrence of the tumor and was well 15 months postoperatively.

Pathological findings

The resected specimen measured about 10 mm in diameter, including peripheral normal mucosa. The cut surface showed a homogeneous, pale tan tissue without obvious hemorrhage or necrosis.

Histologically, the squamous epithelia covering the tumor showed slight hyperkeratosis, but not cellular atypia (Fig. 1). The tumor was composed of elongated blunt-shaped spindle cells intermingled with numerous irregularly dilated blood vessels, which had a thin single layer of endothelial cells (Fig. 2). Mitoses were not noted. The margin of the tumor was circumscribed, despite the absence of a fibrous capsule.

Formalin-fixed, paraffin-embedded sections were immunohistologically stained with the avidin-biotin peroxidase complex method, using commercially available antibodies for desmin, factor VIII, CD-34, α -smooth muscle actin, muscle-specific actin-HHF-35 and myoglobin.

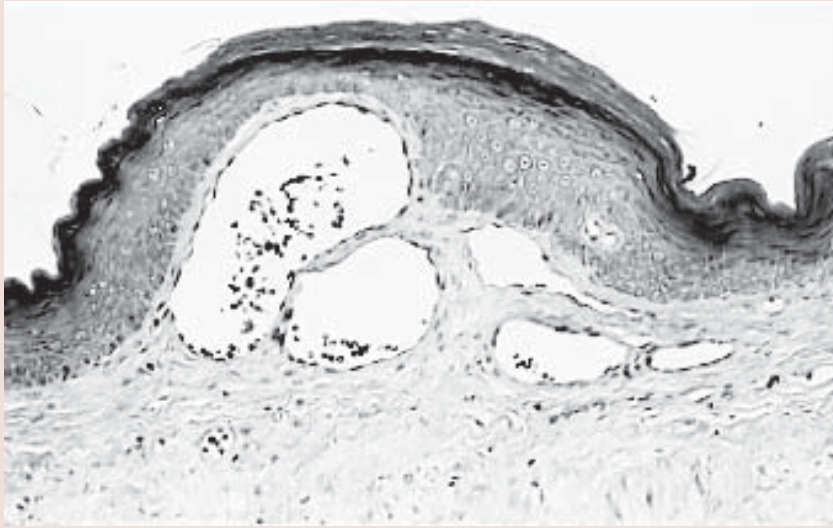


Fig. 1. Solid-type tumor showing compacted vascular vessels and muscles measuring about 8 mm in diameter. This tumor is thickly encapsulated by squamous cells with slight hyperkeratosis (hematoxylin and eosin stain; original magnification $\times 50$).

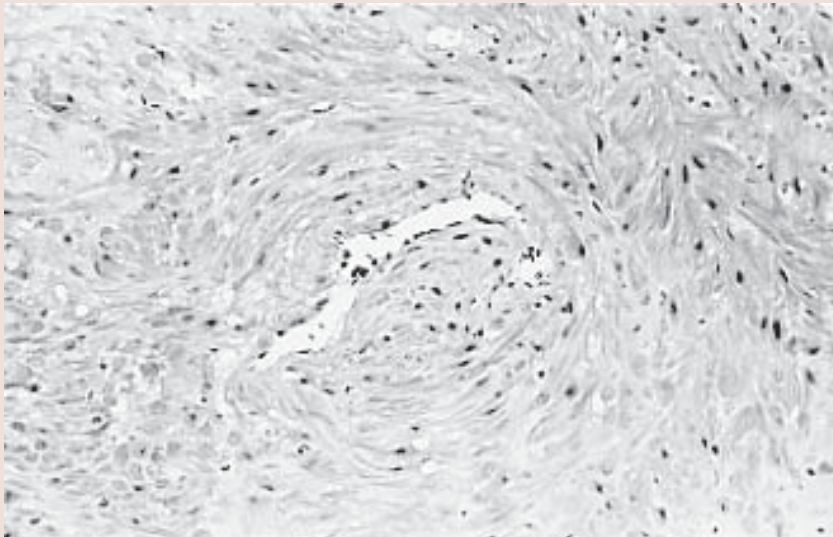


Fig. 2. Thick muscular walled-vessels and intervascular smooth muscle bundles (hematoxylin and eosin stain; original magnification $\times 50$).

The tumor cells as well as the walls of the blood vessels showed marked immunoreactivity for desmin, α -smooth muscle actin (Fig. 3) and muscle-specific actin-HHF-35, but not for myoglobin. The lining endothelial cells of the dilated vessels showed positive immunostaining for factor VIII and CD-34.

Discussion

Leiomyomas developing in the nasal cavity and paranasal sinuses are extremely rare. Maesaka et al. (1966) initially reported an intranasal leiomyoma in 1966. To the best of our knowledge,

35 nasal leiomyomas have been subsequently reported until now. Of these, only 5 tumors developed in the nasal septum (Timiryaleev, 1973; Barr et al., 1990; Trott et al., 1994; Llorente et al., 1996), and 16 cases including the present tumor were histologically classified as vascular type (Table 1), which involved 11 females (mean age: 54.4 years, ranging from 25 to 76) and 5 males (mean age: 55.0 years, ranging from 33 to 77). Prominent clinical symptoms are nasal obstruction and pain, and nasal bleeding is rather less frequent. The tumor developed most frequently in the lower extremities, followed by the upper extremities and less frequently in the nasal septum (Hachisuga et al., 1984). Thus, nasal vascular leiomyoma might be characterized by female predominance, occurrence in aged patients, and nasal obstruction or pain as the primary symptom.

According to the report written by Morimoto (1973), vascular leiomyomas were classified into 3 histological subtypes: solid or capillary, cavernous and venous. The venous type developed most frequently in the head and neck. Histologically, the venous type has vascular channels with thick muscular walls that are easily discernible from smooth muscle bundles, as observed in the present case. Although we conducted immunohistochemical analysis for

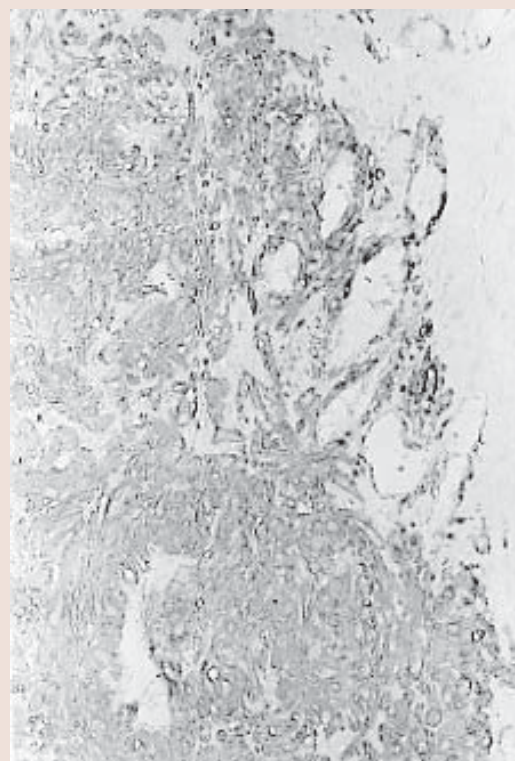


Fig. 3. Most of the spindle cells showing strong positive cytoplasmic reactivity for α -smooth muscle actin on the left side of the lesion (peroxidase anti-peroxidase method for α -smooth muscle actin antigen; original magnification $\times 50$).

Table 1. Reported cases of vascular leiomyoma of the nasal cavity

Authors	Sex/age (year)	Location	Symptom
Maesaka et al. (1966)	F /49	Vestibule	Pain
Schwartzman et al. (1973)	M/57	Maxillary, ethmoid, sphenoid, posterior nasal fossa	Nasal obstruction, headache
Wolfwitz et al. (1973)	F /42	Inferior turbinate	Nasal obstruction
Kambayashi (1978)	F /55	Vestibule	—
McCaffrey et al. (1978)	F /76	Inferior turbinate	Epistaxis
Hanna et al. (1988)	F /64	Inferior turbinate	Nasal obstruction, epistaxis, pain
Zijlker et al. (1989)	M/33	Ethmoid	Periorbital swelling, nasal discharge, nasal obstruction
Ragbeer et al. (1990)	F /49	Anterior nasal floor	Pain, nasal discharge
Sawada et al. (1990)	M/41	Vestibule	Tumor in nostril
Harrison et al. (1993)	F /55	Ethmoid	Epiphora, swelling
Khan et al. (1994)	F /71	Inferior turbinate	Nasal obstruction
Trott et al. (1966)	M/77	Inferior turbinate	Epistaxis
Nall et al. (1996)	F /43	Superior turbinate	Nasal obstruction, epistaxis, pain
Murono et al. (1998)	F /69	Inferior turbinate	Epistaxis
Present case	M/67	Septum	Nasal obstruction

F, female; M, male.

academic interest, histopathological diagnosis is easily done with routinely stained hematoxylin and eosin sections. Malignant transformation of vascular leiomyoma has not been reported, in spite of local recurrence in a few cases (2 of 562 cases) (Hachisuga, 1984). It should be stressed that otorhinolaryngologists should have an awareness of the possible existence of vascular leiomyoma in the nasal cavity.

References

- 1 Barr GD, More IAR, McCallum HM. Leiomyoma of the nasal septum. *J Laryngol Otol* 1990; 104:891–893.
- 2 Batsakis JG (ed). *Tumors of the head and neck: clinical and pathological considerations*. 2nd ed. Baltimore, MD: Williams & Wilkins; 1979. p. 354–356.
- 3 Enzinger FM, Weiss SW. *Soft tissue tumors*. 3rd ed. St Louis: Mosby; 1995. p. 467–489.
- 4 Hachisuga T, Hashimoto H, Enjoji M. Angioleiomyoma: a clinicopathologic reappraisal of 562 cases. *Cancer* 1984;54:126–130.
- 5 Hanna GS, Akosa AB, Ali MH. Vascular leiomyoma of the inferior turbinate: report of a case and review of the literature. *J Laryngol Otol* 1988;102:1159–1160.
- 6 Harrison D, Lund VJ. Tumors of muscle origin. In: Harrison D, Lund VJ, eds. *Tumours of the upper jaw*. Edinburgh, United Kingdom: Churchill Livingstone; 1993. p.187–197.
- 7 Kambayashi J. Vascular leiomyoma of the nasal vestibule. *J Jpn Otolaryngol (Tokyo)* 1976;50: 313–316.
- 8 Khan MHZ, Jones AS, Haqqani MT. Angioleiomyoma of the nasal cavity: report of a case and review of the literature. *J Laryngol Otol* 1994; 108:244–246.
- 9 Llorente JL, Suarez C, Seco M, Garcia A. Leiomyoma of the nasal septum: report of a case and review of the literature. *J Laryngol Otol* 1996; 110:65–68.
- 10 Maesaka A, Keyaki Y, Nakanishi T. Nasal angioleiomyoma and leiomyosarcoma: report of 2 cases. *Otologia (Fukuoka)* 1966;12:42.
- 11 McCaffrey TV, McDonald TJ, Unni KK. Leiomyoma of the nasal cavity: report of a case. *J Laryngol Otol* 1978;92:817–819.
- 12 Morimoto N. Angioleiomyoma (vascular leiomyoma): a clinicopathologic study. *Med J Kagoshima Univ* 1973;24:663–683.
- 13 Muro S, Ohmura T, Sugamori S, Furukawa M. Vascular leiomyoma with abundant adipose cells of the nasal cavity. *Am J Otolaryngol* 1998;19: 50–53.
- 14 Nall AV, Stringer SP, Baughman RA. Vascular leiomyoma of the superior turbinate: first report case. *Head Neck* 1996;19:63–67.
- 15 Ragbeer MS, Stone J. Vascular leiomyoma of the nasal cavity: report of a case and review of literature. *J Oral Maxillofac Surg* 1990;48:1113–1117.
- 16 Sawada Y. Angioleiomyoma of the nasal cavity. *J Oral Maxillofac Surg* 1990;48:1100–1101.
- 17 Schwartzman J, Schwartzman J. Leiomyoangioma of paranasal sinuses: case report. *Laryngoscope* 1973;83:1856–1858.
- 18 Timiryaleev, MKH. Angioleiomyoma of the nasal septum. *Vestn Otolaryngol* 1973;35:106.
- 19 Trott MS, Gewirtz A, Lavertu P, Wood BG, Sebek BA. Sinonasal leiomyomas. *Otolaryngol Head Neck Surg* 1994;111:660–664.
- 20 Wolfwitz BL, Schmaman A. Smooth muscle tumours of the upper respiratory tract. *S Afr Med J* 1973;47:1189–1191.
- 21 Zijlker TD, Visser R. A vascular leiomyoma of the ethmoid. Report of case. *Rhinology* 1989; 27:129–135.

Received September 25, 2002; accepted October 7, 2002

Corresponding author: Mitsuhiro Osaki